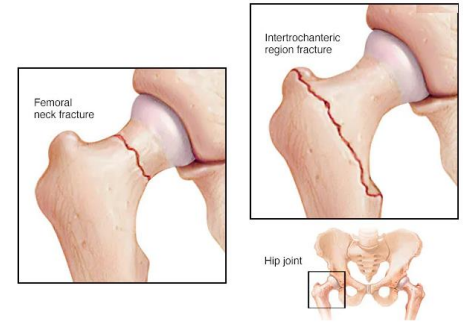


Anesthésie Locorégionale pour les Fractures de la Hanche.



DR BOUARROUDJ NOREDDINE

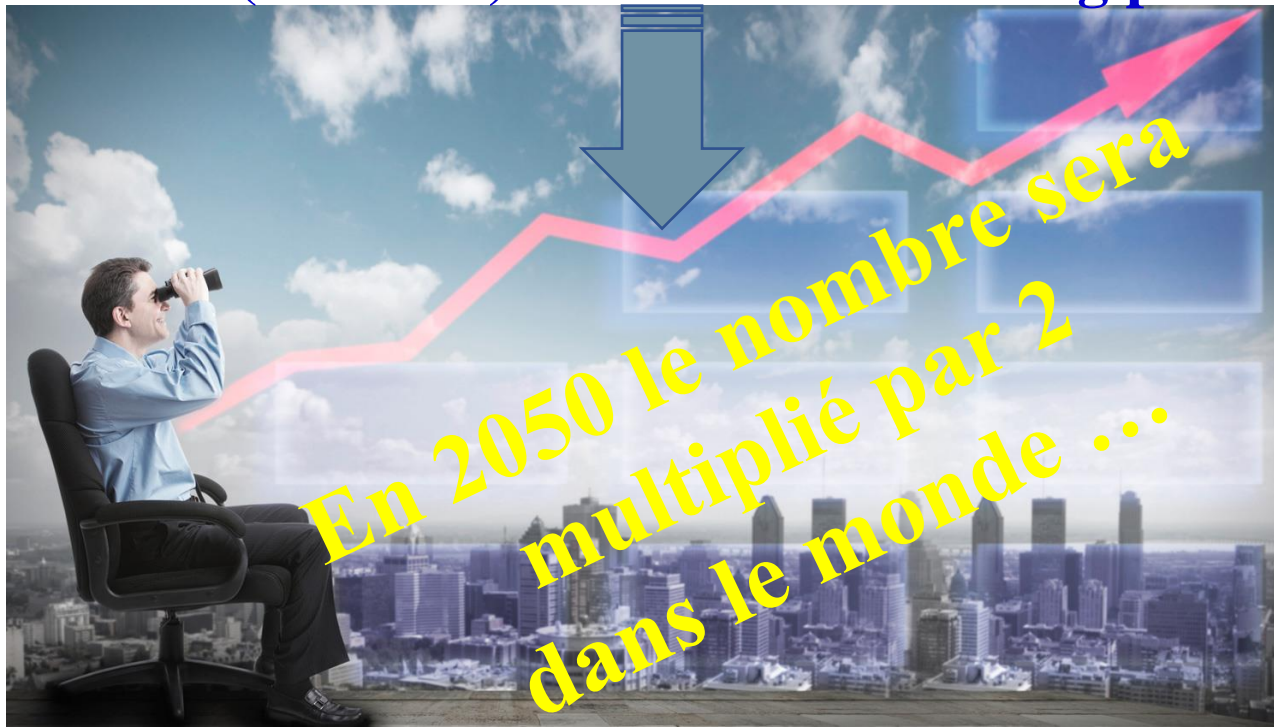Clinique *Maissa lyne* ميسالين

Anesthesie.CLUB

Fractures de la Hanche



- UK : 65000 / AN
- USA : 300000 / AN
- France :  50000  16000 /AN
- Previsions de l'American Society of Bone and Mineral Research (ASBMR) 2022 Annual Meeting pour 2050:



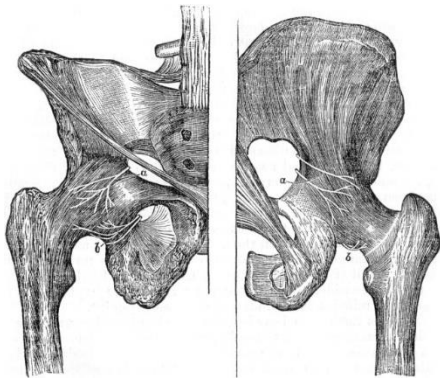
HISTORY OF ANESTHESIA : 1898

Dr. August Bier (1861-1949)-Conducts the **First Spinal Anesthetic** using cocaine.

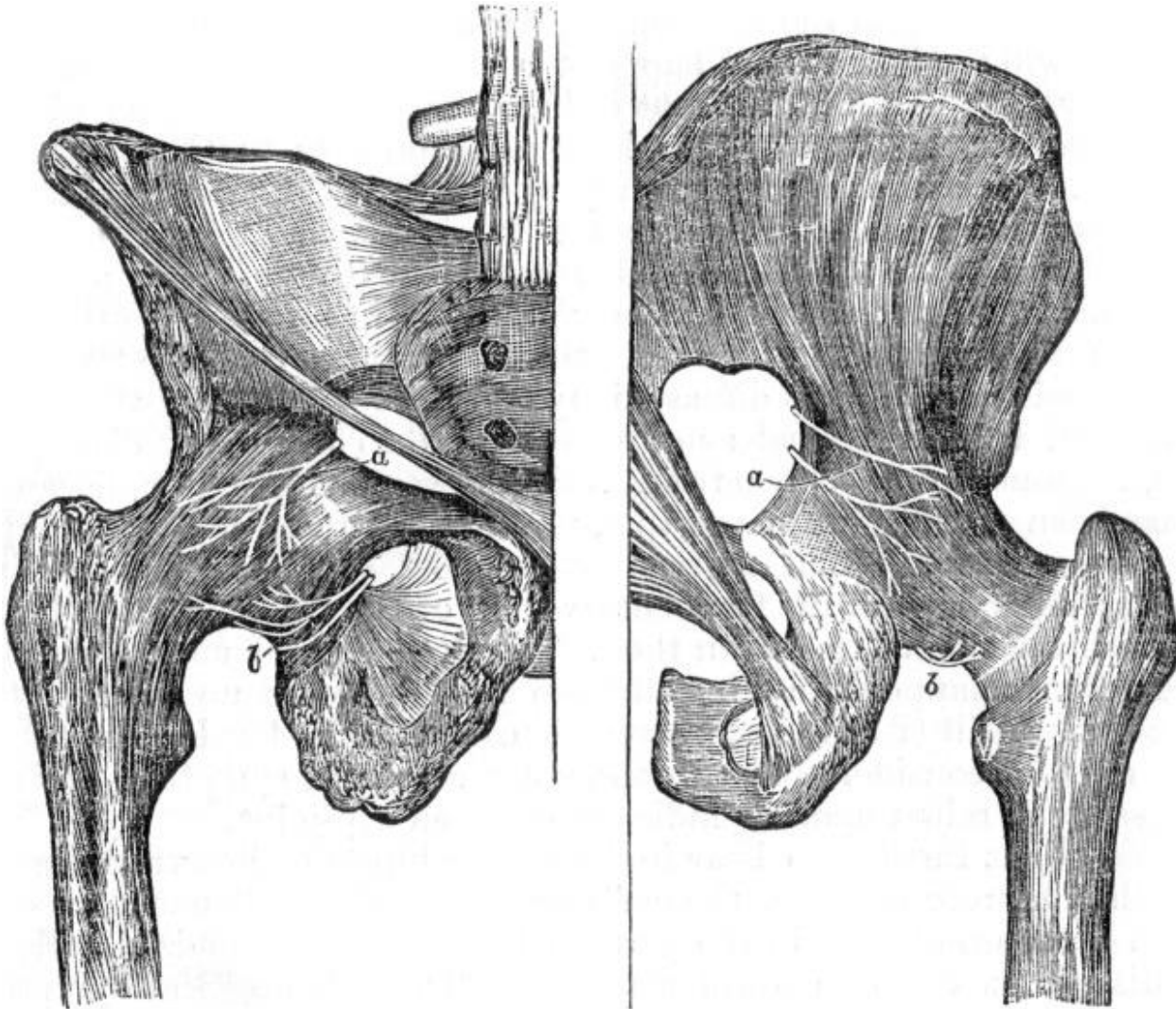
HISTORY OF ANESTHESIA : 1900

Caudal Epidural Analgesia is described independently by France's Drs. **Jean-Anthanase Sicard and Fernand Cathelin**. Their innovation comes after an inadvertent epidural injection by **Dr. J. Leonard**...

BASES ANATOMIQUES ET PHYSIOPATHOLOGIQUES



INNERVATION DE L'ARTICULATION COXO-FÉMORALE



INNERVATION DE L'ARTICULATION COXO-FÉMORALE

HILTON'S LOW 1863



John Hilton 1804-1878

The Nerves supplying the Joint capsule also supply the Muscles regulating the movement of the joint and the Skin over the joint.

INNERVATION DE L'ARTICULATION COXO-FÉMORALE

La loi de Hilton = Puissant Tremplin
comprendre l'anatomie
et la physiopathologie articulaires...

1. Compréhension traditionnelle de l'innervation des articulations
2. Compréhension futuriste +++

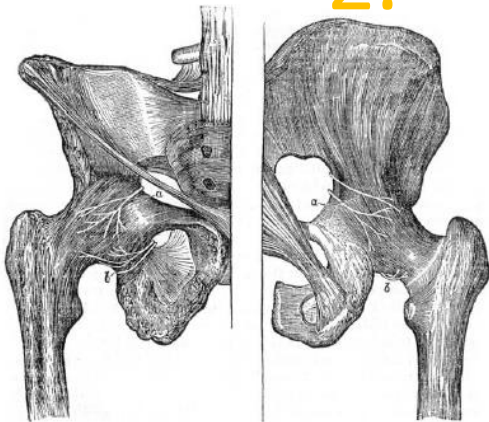


Fig. 3. Articular branches of the anterior and posterior hip joint (Reproduced from Hilton's book, Figs. 62 and 63, p. 193): left, (a) femoral nerve and (b) obturator nerve; right, (a) sacral plexus and (b) obturator nerve.

INNERVATION DE L'ARTICULATION COXO-FÉMORALE

Clinical Anatomy 27:548–555 (2014)

A GLIMPSE OF OUR PAST

Hilton's Law Revisited

MARIE-NOËLLE HÉBERT-BLOUIN,¹ R. SHANE TUBBS,²
STEPHEN W. CARMICHAEL,^{3,4} AND ROBERT J. SPINNER^{1,3,4*}

¹*Department of Neurologic Surgery, Mayo Clinic, Rochester, Minnesota*

²*Pediatric Neurosurgery, Children's Hospital, Birmingham, Alabama*

³*Department of Orthopedics, Mayo Clinic, Rochester, Minnesota*

⁴*Department of Anatomy, Mayo Clinic, Rochester, Minnesota*

Hilton's Law, put forth 150 years ago, is well known and frequently taught in anatomy courses. We critically analyzed the complex description of associated muscular, cutaneous, and articular innervations in order to assess the general applicability of Hilton's Law. We applied rules for interpretation of the Law extrapolated upon but based on Hilton's original writings, and excluded obscure supplementary clauses not considered as part of the Law. We found the Law, as originally written and as we interpreted with some latitude, to be reliable and applicable to all cranial and peripheral nerves. Hilton's Law is a powerful springboard to understand articular anatomy and pathophysiology. Clin. Anat. 27:548–555, 2014. © 2013 Wiley Periodicals, Inc.

1863-----2022 Cette loi
« PROPHETIQUE » reste
applicable à l'anatomie !!!!

DERMATOMES MYOTOMES ET OSTEOTOMES

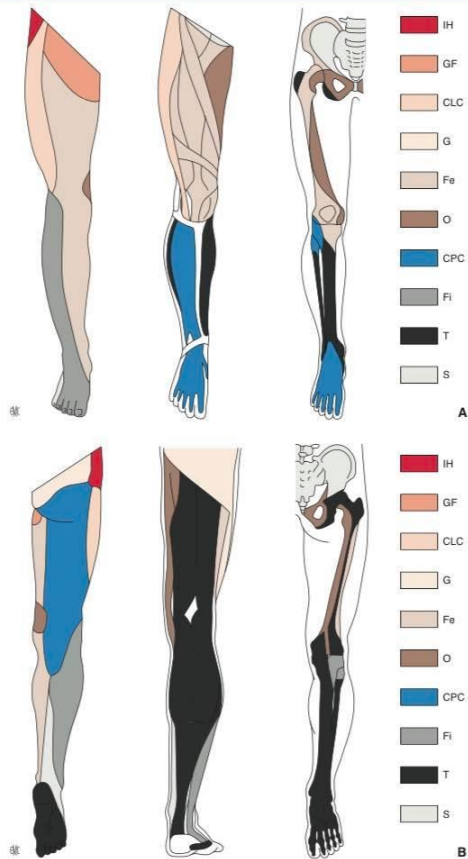


Figure 4. Représentation schématique des territoires d'innervation sensitivomotrice du membre inférieur.
A. Face antérieure.
B. Face postérieure. *Noter l'absence de superposition stricte entre les dermatomes, les myotomes et les sclérotomes. De plus, il peut exister d'importantes variations individuelles, par exemple l'absence de nerf cutané latéral de la cuisse qui est alors remplacé par des branches cutanées issues des nerfs subcostal et fémoral.* IH: nerf iliohypogastrique; GF: nerf génito-fémoral; CLC: nerf cutané latéral de la cuisse; G: nerfs glutéaux supérieur et inférieur; Fe: nerf fémoral; O: nerf obturateur; CPC: nerf cutané postérieur de la cuisse; FI: nerf fibulaire commun; T: nerf tibial; S: nerf sural.

Absence de
Superposition +++

INNERVATION DE L'ARTICULATION COXO-FÉMORALE

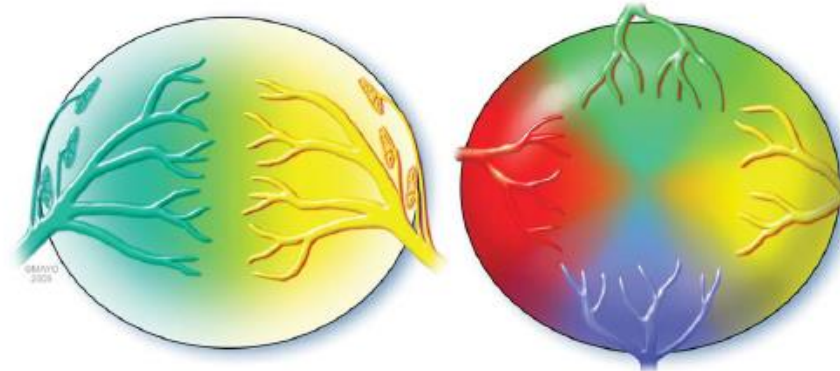
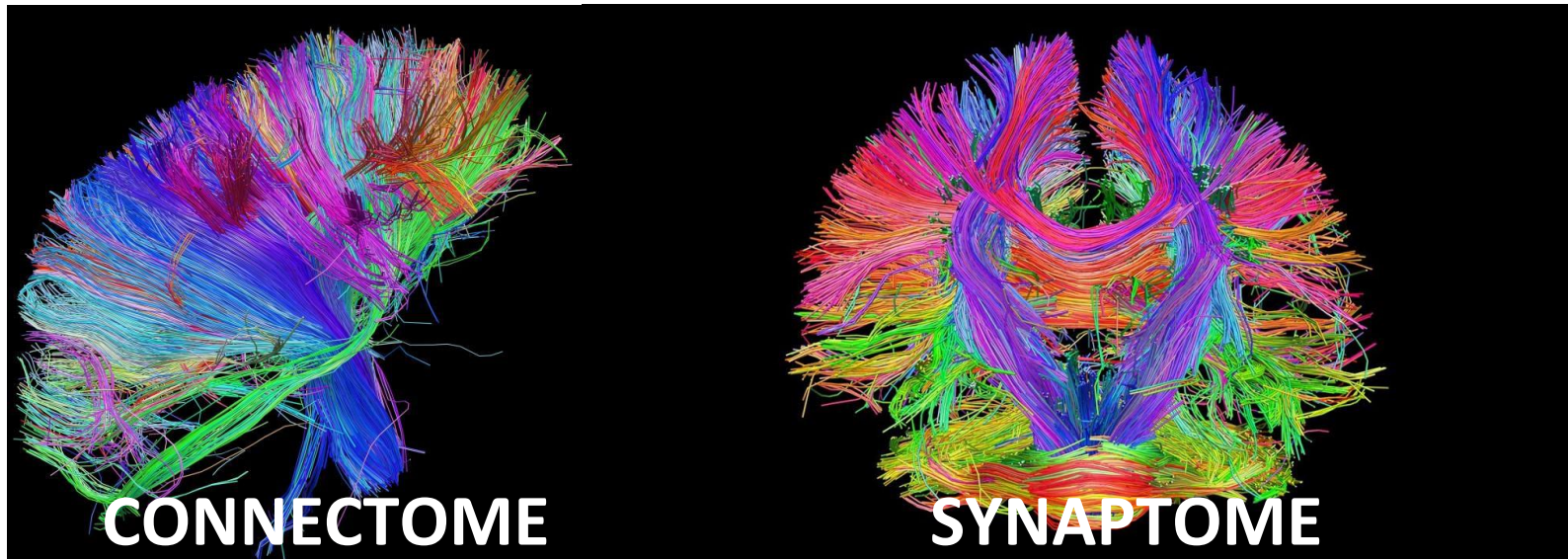


Fig. 4. Innervation patterns or "capsulotomes". Left, hemispheric representation of a simple joint with dual innervation, such as of the superior tibiofibular joint, by fibular (peroneal) and tibial nerves. Right, "quadrant" type innervation representative of a more complex joint (reproduced with permission from Mayo Foundation, 2009).

CAPSULOTOME

INNERVATION DE L'ARTICULATION COXO-FÉMORALE

Pain Medicine, 22(5), 2021, 1149–1157

doi: 10.1093/pm/pnab061

Advance Access Publication Date: 10 February 2021

Review Article

OXFORD

Sensory Innervation of the Hip Joint and Referred Pain: A Systematic Review of the Literature

Pierre Laumonerie,^{*,†} Yoann Dalmas,^{*} Meagan E. Tibbo,[‡] Suzanne Robert,^{*} Thibault Durant,^{*}
Thomas Caste,^{*} Tristan Vialla,[§] Joris Tiercelin,^{*} Gauthier Gracia,^{*} and Patrick Chaynes[†]

^{*}Department of Orthopaedic Surgery, Hôpital Pierre Paul Riquet, Toulouse, France; [†]Anatomy Laboratory, Rangueil University Hospital, Toulouse, France; [‡]Department of Orthopedic Surgery, Mayo Clinic, Rochester, Minnesota, USA; and [§]Department of Orthopaedic Surgery, Centre Hospitalier Universitaire de Reims, Reims, France

Correspondence to: Pierre Laumonerie, MD, MSc, Place du Docteur Baylac, Toulouse, 31059, France. E-mail: laumonerie.pierre@hotmail.fr.

Funding source: Figures 2, 4, and 5 of the present study were funded by ADLER ORTHO France.

Conflicts of interest: The authors report no conflicts of interest with respect to the materials or methods used in this study or the findings specified herein. Neither the authors nor any members of their families have received any financial remuneration related to the subject of the article.

Authors Pierre Laumonerie and Yoann Dalmas contributed equally to this study.

LE 22^{ÈME} CONGRÈS NATIONAL DE LA SAARSIU Alger, Le 15, 16 et
le 17 Décembre 2022

INNERVATION DE L'ARTICULATION COXO-FÉMORALE

Pain Medicine, 22(5), 2021, 1149–1157

doi: 10.1093/pm/pnab061

Advance Access Publication Date: 10 February 2021

Review Article

OXFORD

Sensory Innervation of the Hip Joint and Referred Pain: A Systematic Review of the Literature

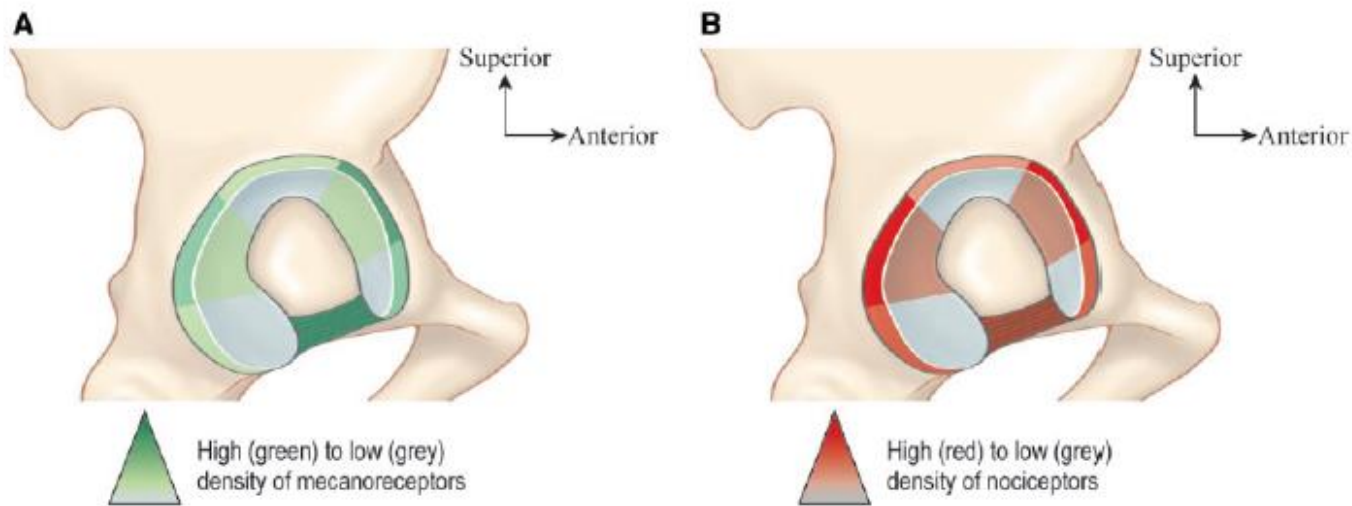


Figure 2. Summary of sensory innervation of the acetabular labrum and cartilage: (A) mechanoreceptor density and (B) nociceptor density.

INNERVATION DE L'ARTICULATION COXO-FÉMORALE

Pain Medicine, 22(5), 2021, 1149–1157

doi: 10.1093/pm/pnab061

Advance Access Publication Date: 10 February 2021

Review Article

OXFORD

Sensory Innervation of the Hip Joint and Referred Pain: A Systematic Review of the Literature

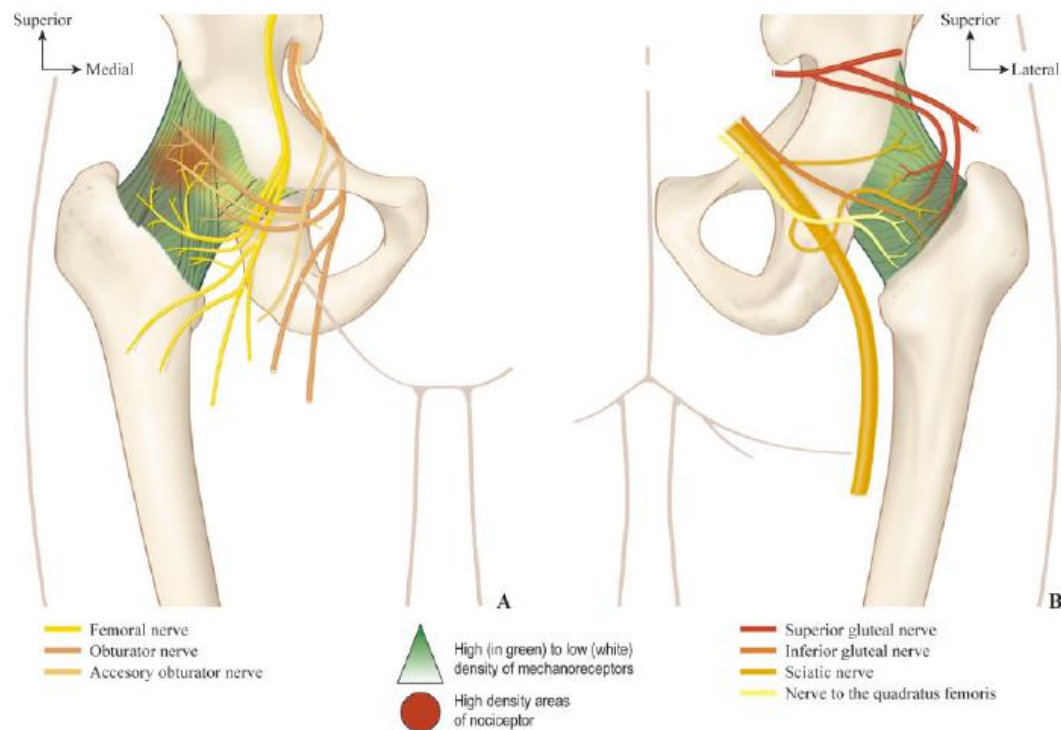


Figure 4. Summary of the sensory innervation of the hip joint based on review of the literature: (A) anterior and (B) posterior views.

INNERVATION DE L'ARTICULATION COXO-FÉMORALE

Pain Medicine, 22(5), 2021, 1149–1157

doi: 10.1093/pm/pnab061

Advance Access Publication Date: 10 February 2021

Review Article

OXFORD

Sensory Innervation of the Hip Joint and Referred Pain: A Systematic Review of the Literature

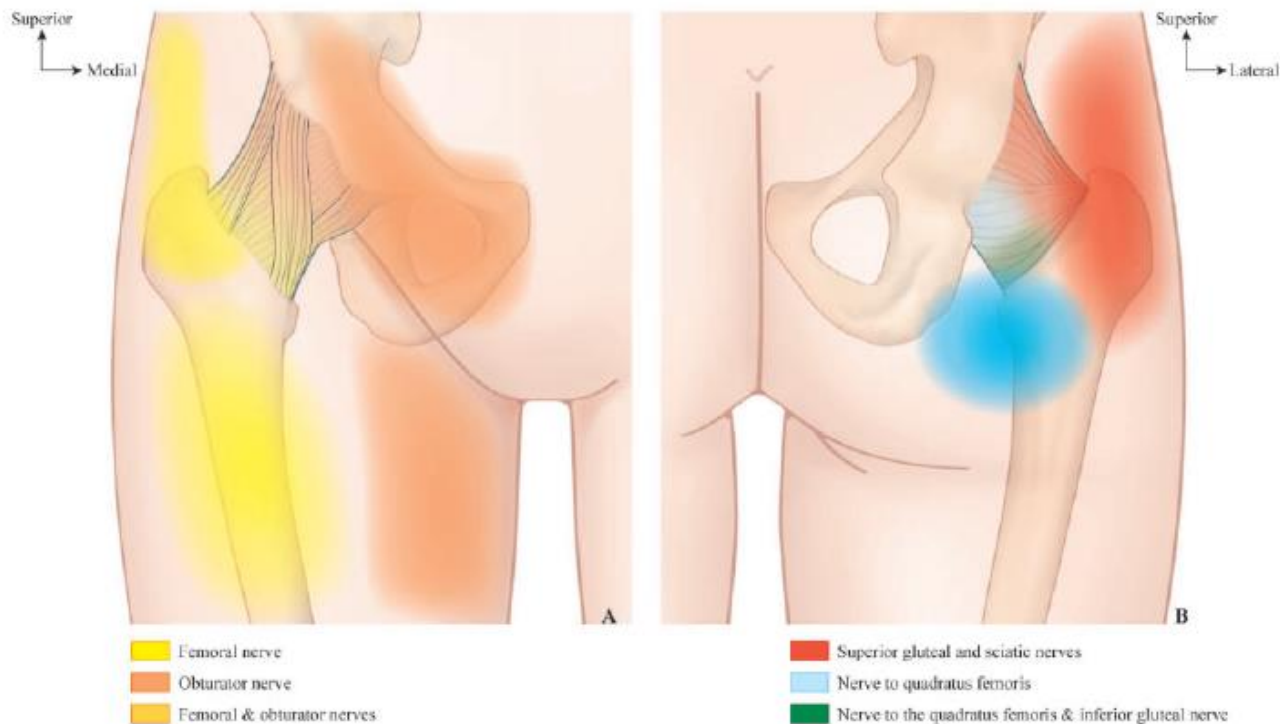


Figure 5. Seeing the forest through the trees. Visual representation of the anatomic regions supplied by nerves, which simultaneously innervate the hip capsule. The richly innervated areas of the anterior (A) and posterior (B) hip capsule are representative of the “forest,” which can sometimes elude providers who may be focused on areas of RP—the “trees.”

La douleur projetée = L'arbre qui cache la forêt

Pain Medicine, 22(5), 2021, 1149–1157

doi: 10.1093/pm/pnab061

Advance Access Publication Date: 10 February 2021

Review Article

OXFORD

Sensory Innervation of the Hip Joint and Referred Pain: A Systematic Review of the Literature

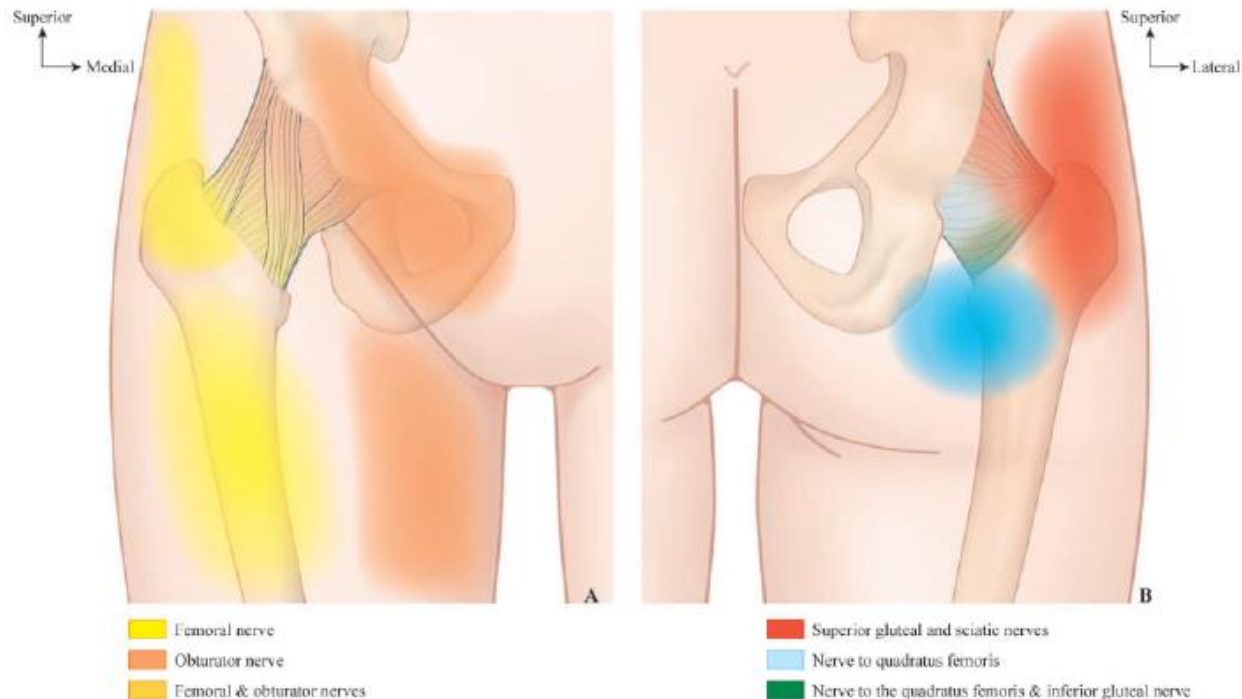


Figure 5. Seeing the forest through the trees. Visual representation of the anatomic regions supplied by nerves, which simultaneously innervate the hip capsule. The richly innervated areas of the anterior (A) and posterior (B) hip capsule are representative of the “forest,” which can sometimes elude providers who may be focused on areas of RP—the “trees.”

La métaphore : L'arbre qui cache la forêt...



La douleur projetée = L'arbre qui cache la forêt...
LA FORET = ARTICULATION COXO FEMORALE

TECHNIQUES D'ALR POUR LES FRACTURES DE LA HANCHE

- **BLOCS NERVEUX CENTRAUX:**

1. Rachianesthésie.
2. Anesthésie péridurale.

- **BLOCS PERIPHERIQUES:**

1. Bloc du Nerf Fémoral.
2. Bloc Ilio-Fascial.
3. Quadratus Lumborum Block.
4. ESP Block.
5. PENG Block.
6. Bloc du Plexus Lombaire.
7. Bloc du Nerf Latéral Cutané de la Cuisse

Intérêt ALR échoguidée

- **Analgésie post opératoire efficace +++.**
- **↓ Besoins opiacés ↓ Effets secondaires.**
- **↓ Nausées Vomissements et iléus.**
- **Anesthésie opératoire si AG et rachi Cl.**
- **RAAC Réhabilitation +++.**

GUIDELINES

ALR échoguidée préférée à l'AG +++++

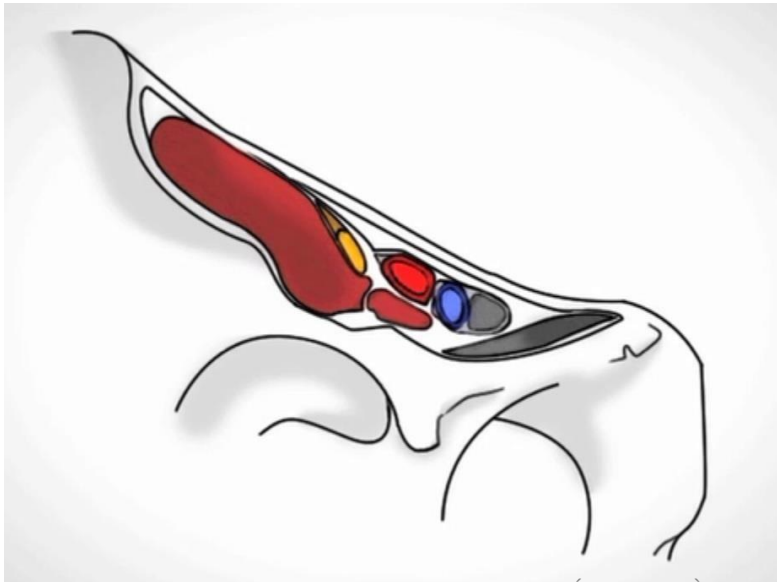
Guidage écho pour Blocs Nerveux



American Society of
Anesthesiologists™

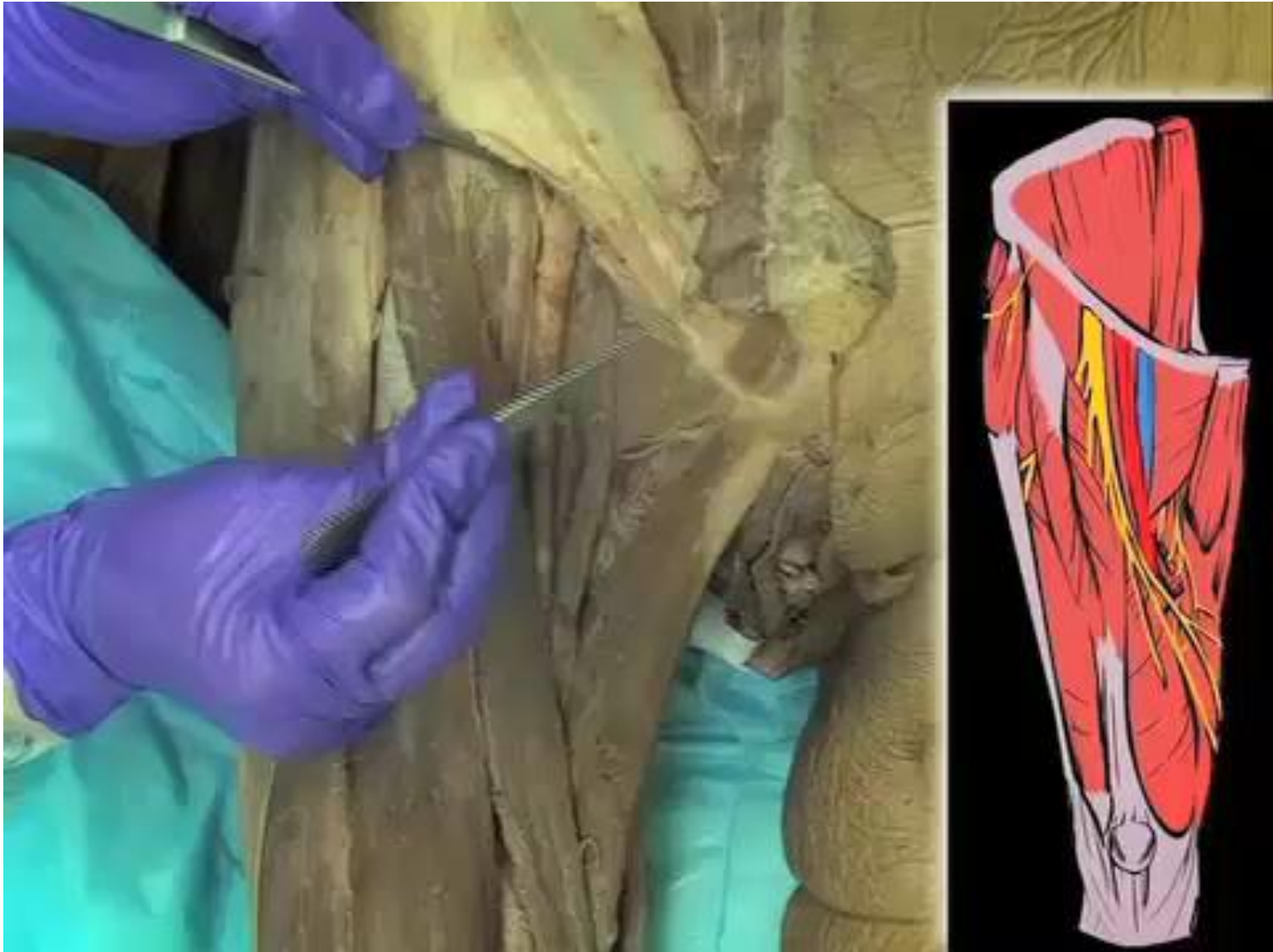

Bloc du nerf Fémoral



BASES ANATOMIQUES

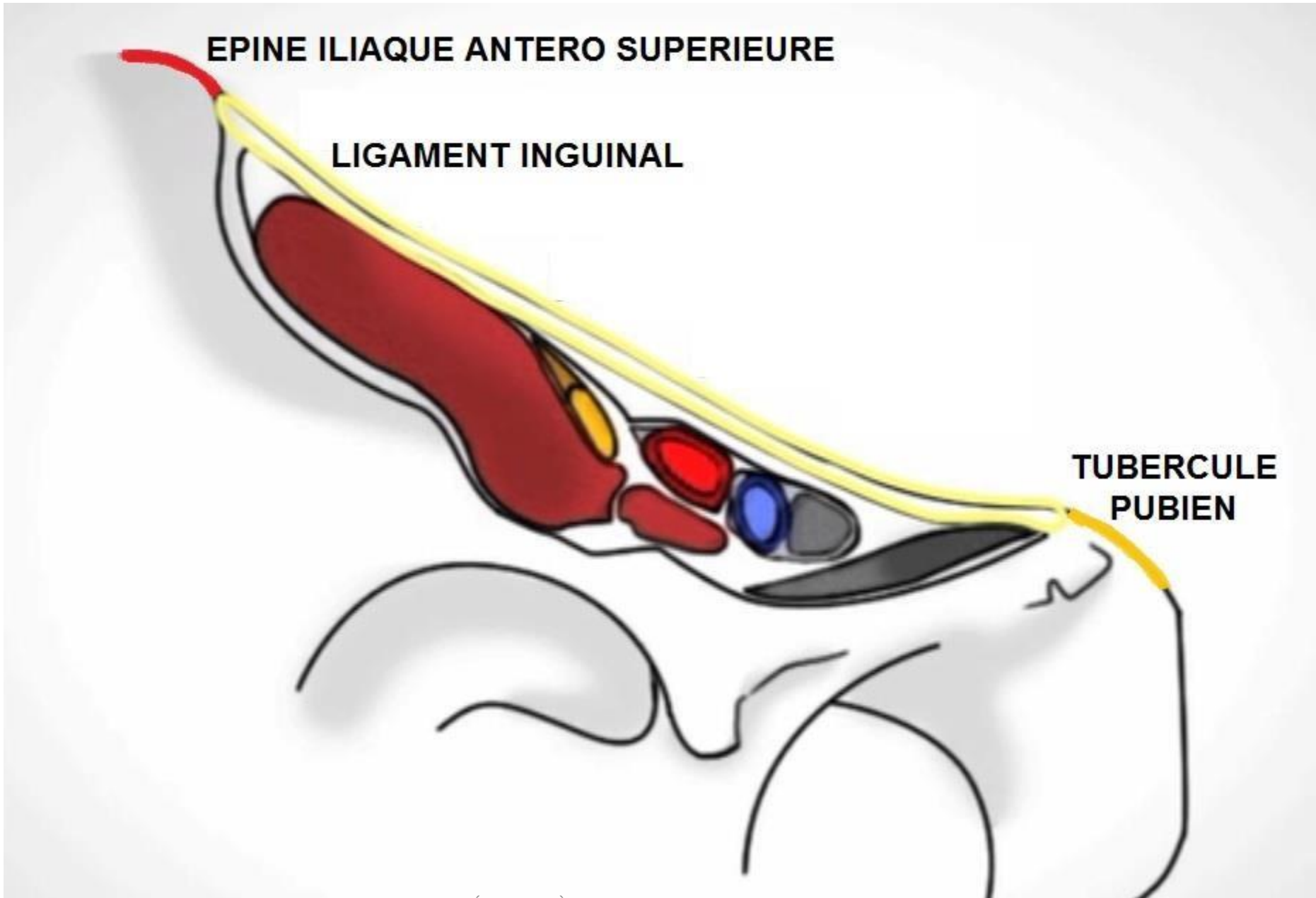
Dissection du nerf Fémoral , Fascia Lata et Fascia Iliaca



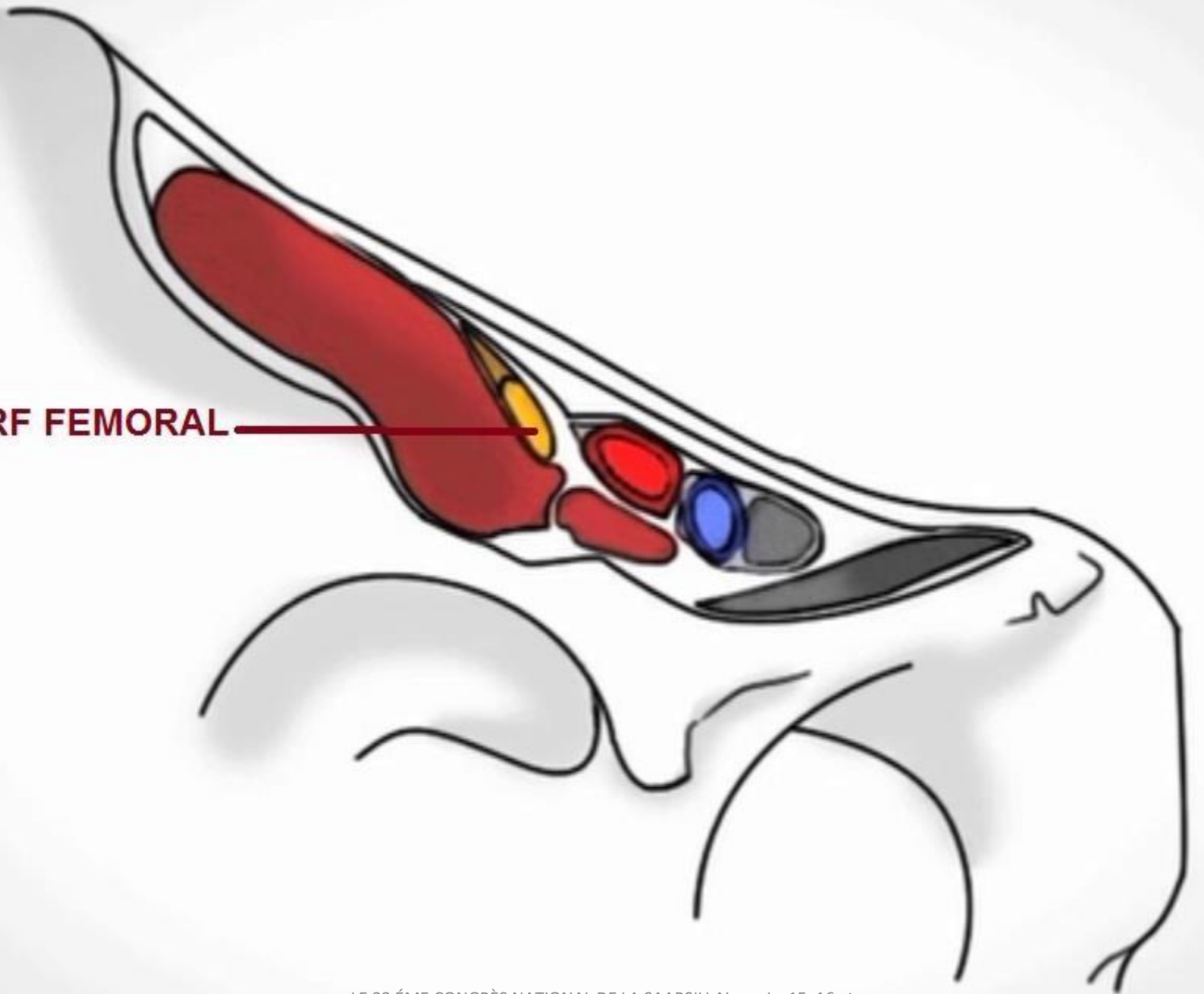
EPINE ILIAQUE ANTERO SUPERIEURE

LIGAMENT INGUINAL

**TUBERCULE
PUBIEN**



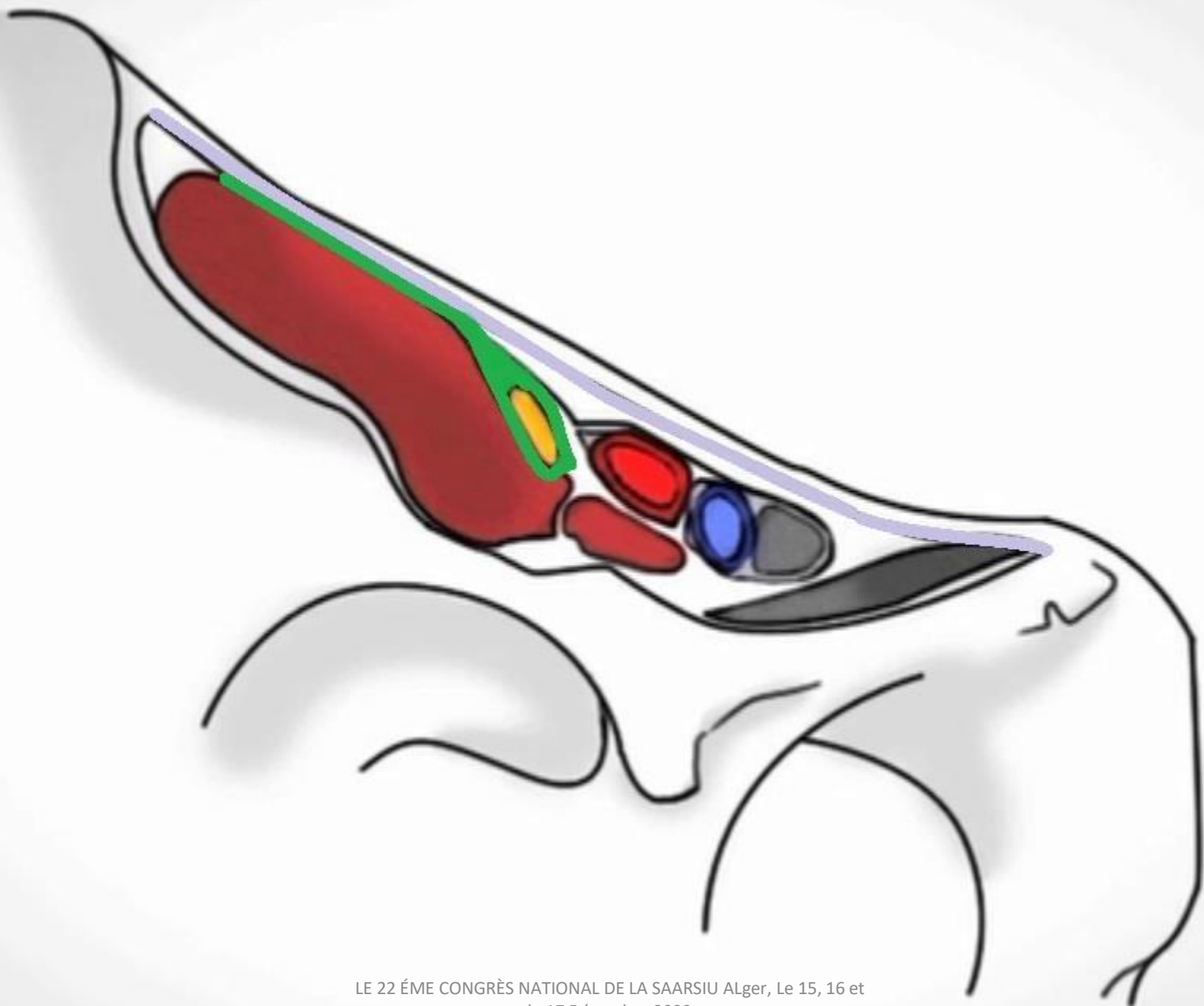
NERF FEMORAL





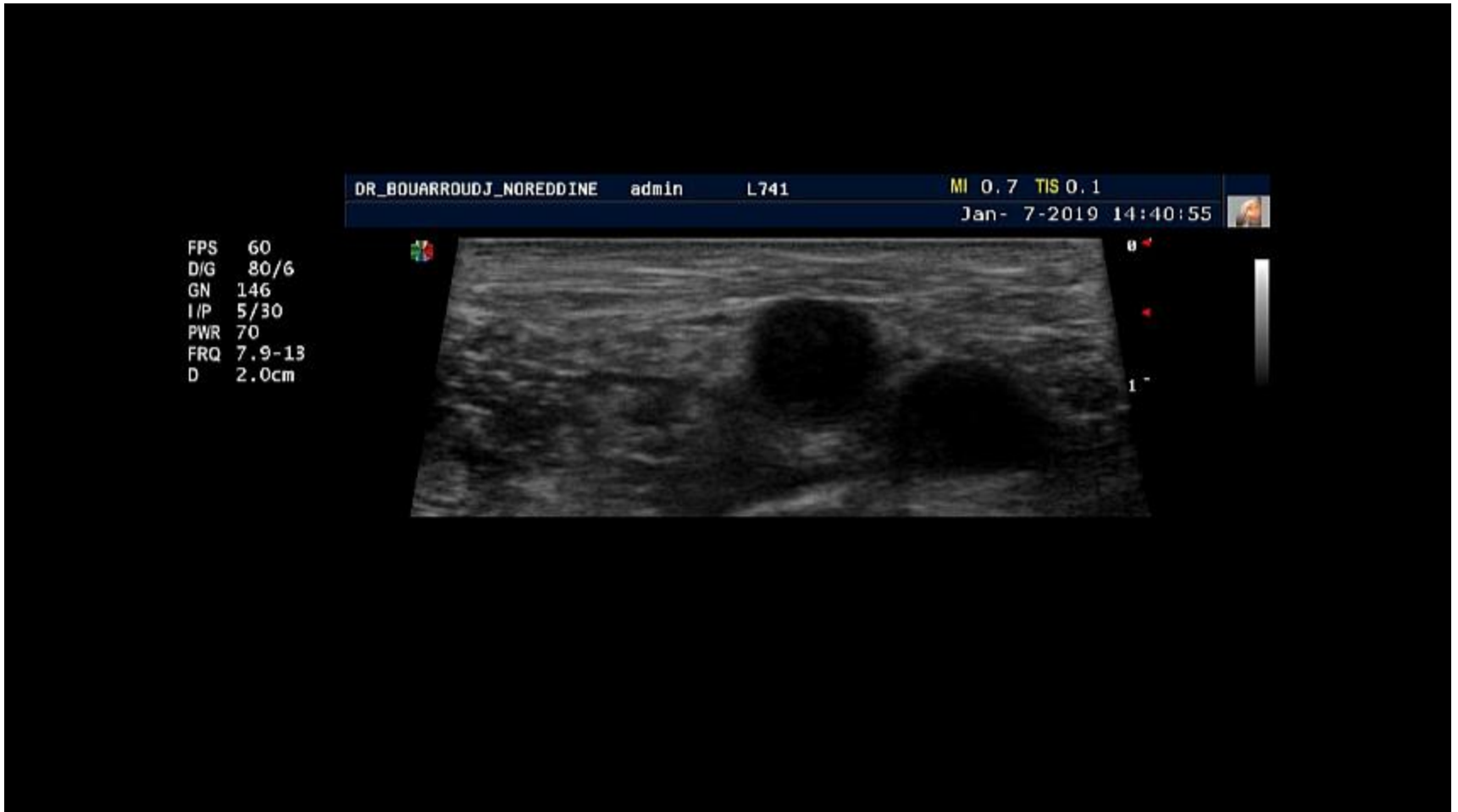MUSCLE ILIAQUE

MUSCLE PSOAS



LE 22 ÉME CONGRÈS NATIONAL DE LA SAARSIU ALger, Le 15, 16 et
le 17 Décembre 2022

SONOANATOMIE



DR_BOUARROUDJ_NOREDDINE admin

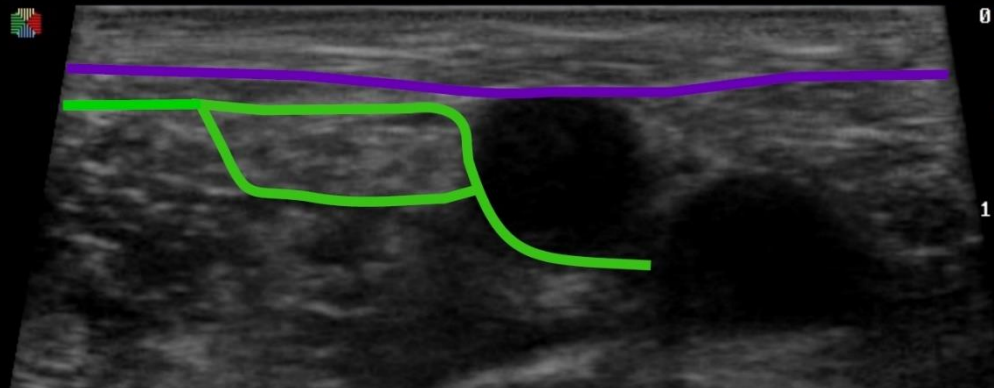
L741

MI 0.7 TIS 0.1

Jan- 7-2019 14:40:55



FPS 60
D/G 80/6
GN 146
I/P 5/30
PWR 70
FRQ 7.9-13
D 2.0cm



DR_BOUARROUDJ_NOREDDINE

admin

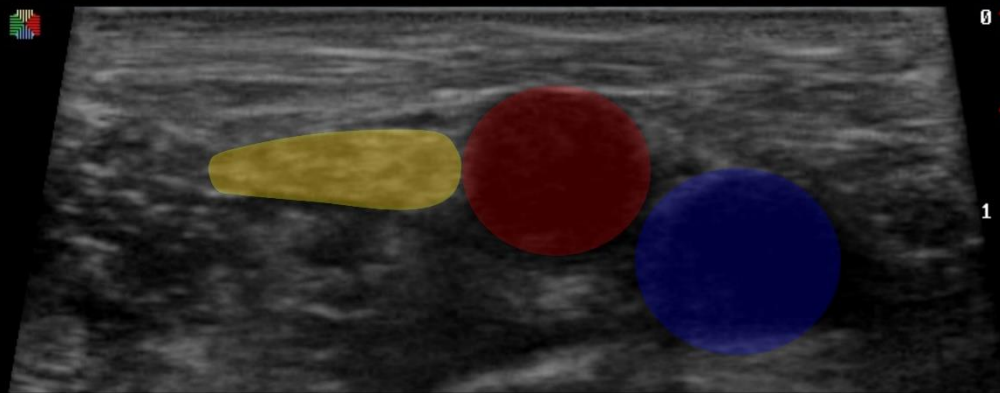
L741

MI 0.7 TIS 0.1

Jan- 7-2019 14:40:55



FPS 60
D/G 80/6
GN 146
I/P 5/30
PWR 70
FRQ 7.9-13
D 2.0cm



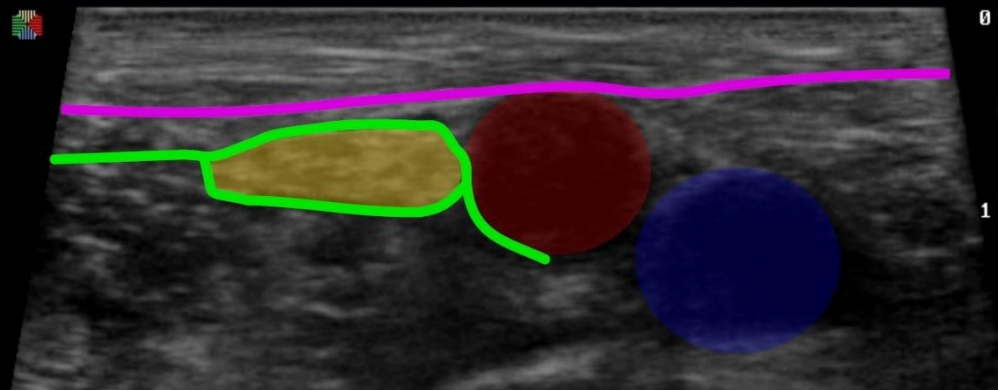DR_BOUARROUDJ_NOREDDINE admin

L741

MI 0.7 TIS 0.1

Jan- 7-2019 14:40:55

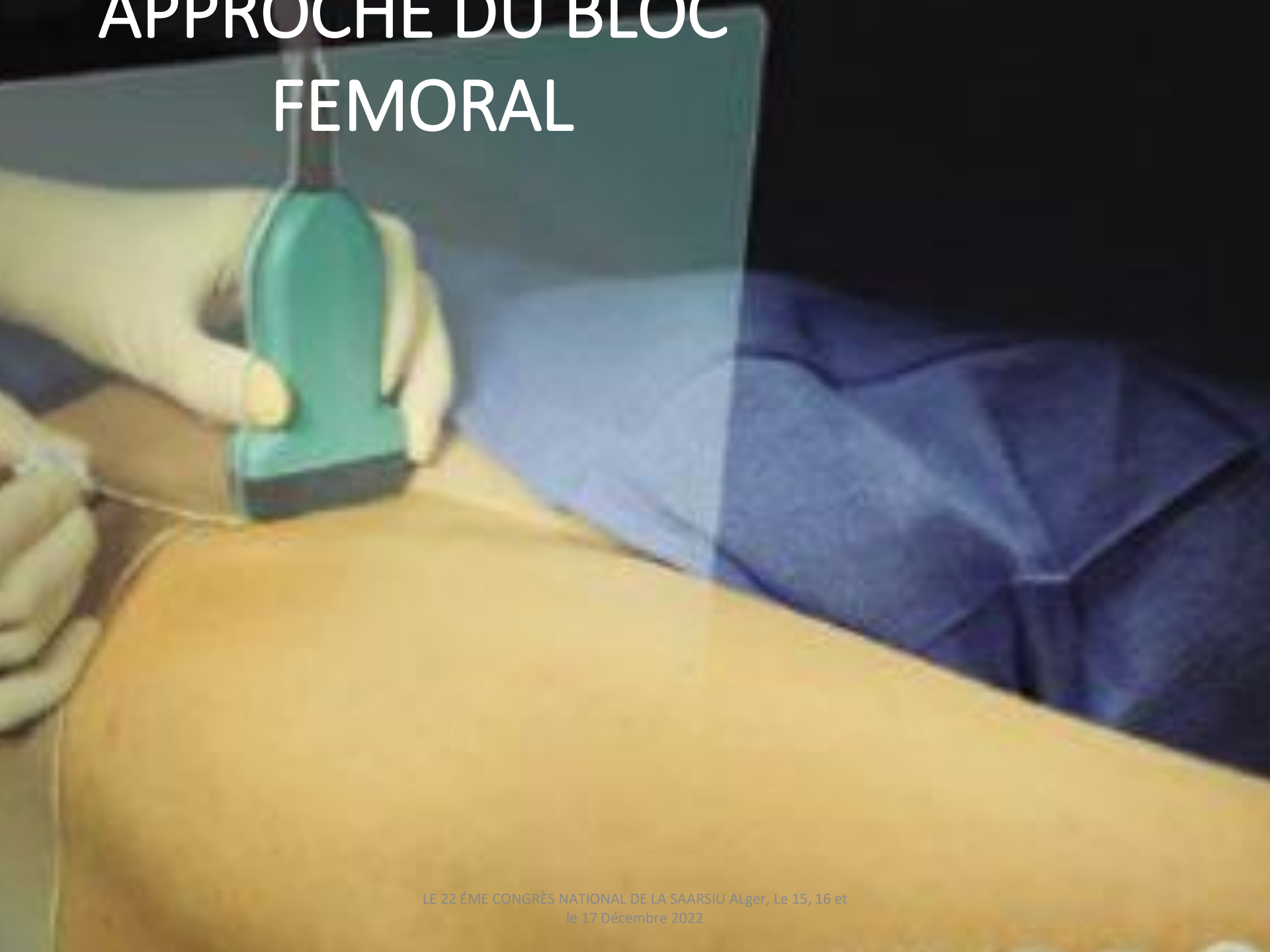
FPS 60
D/G 80/6
GN 146
I/P 5/30
PWR 70
FRQ 7.9-13
D 2.0cm



TECHNIQUE DU BLOC FEMORAL

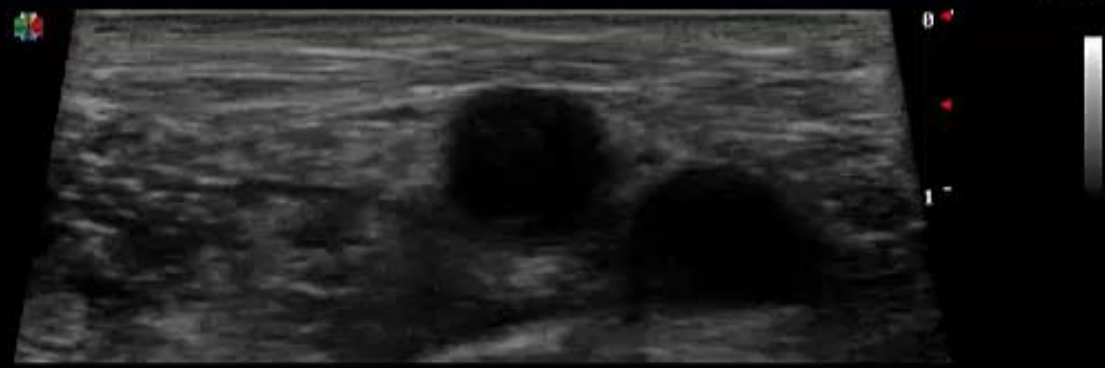
- **INDICATIONS:** Chirurgie fémur, face interne cuisse , tendons quadriceps et analgésie des # hanche et genou
- **SONDE:** linéaire
- **POSITION:** DD
- **AIGUILLE:** 22 G 5-10cm
- **NEUROSTIMULATION:** contraction quadriceps
- **VOLUME:** 10 – 20 ml

APPROCHE DU BLOC FEMORAL

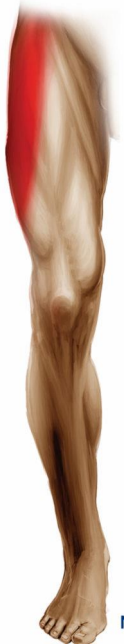

DR_BOUARROUDJ_NOREDDINE admin L741 MI 0.7 TIS 0.1
Jan- 7-2019 14:40:55

FPS 60
D/G 80/6
GN 146
I/P 5/30
PWR 70
FRQ 7.9-13
D 2.0cm



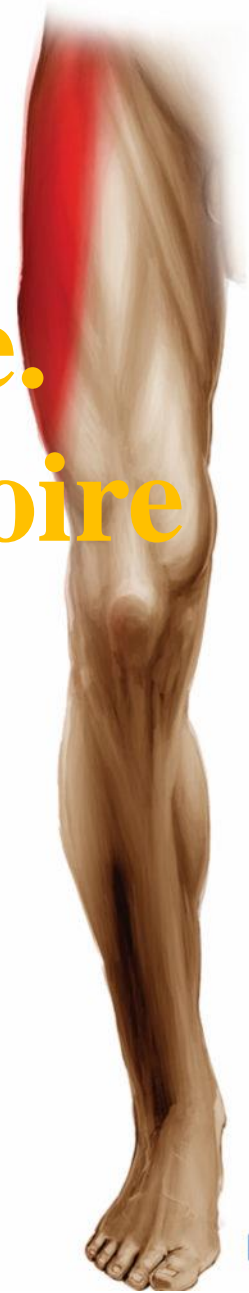Bloc du Nerf Cutané Latéral de la Cuisse

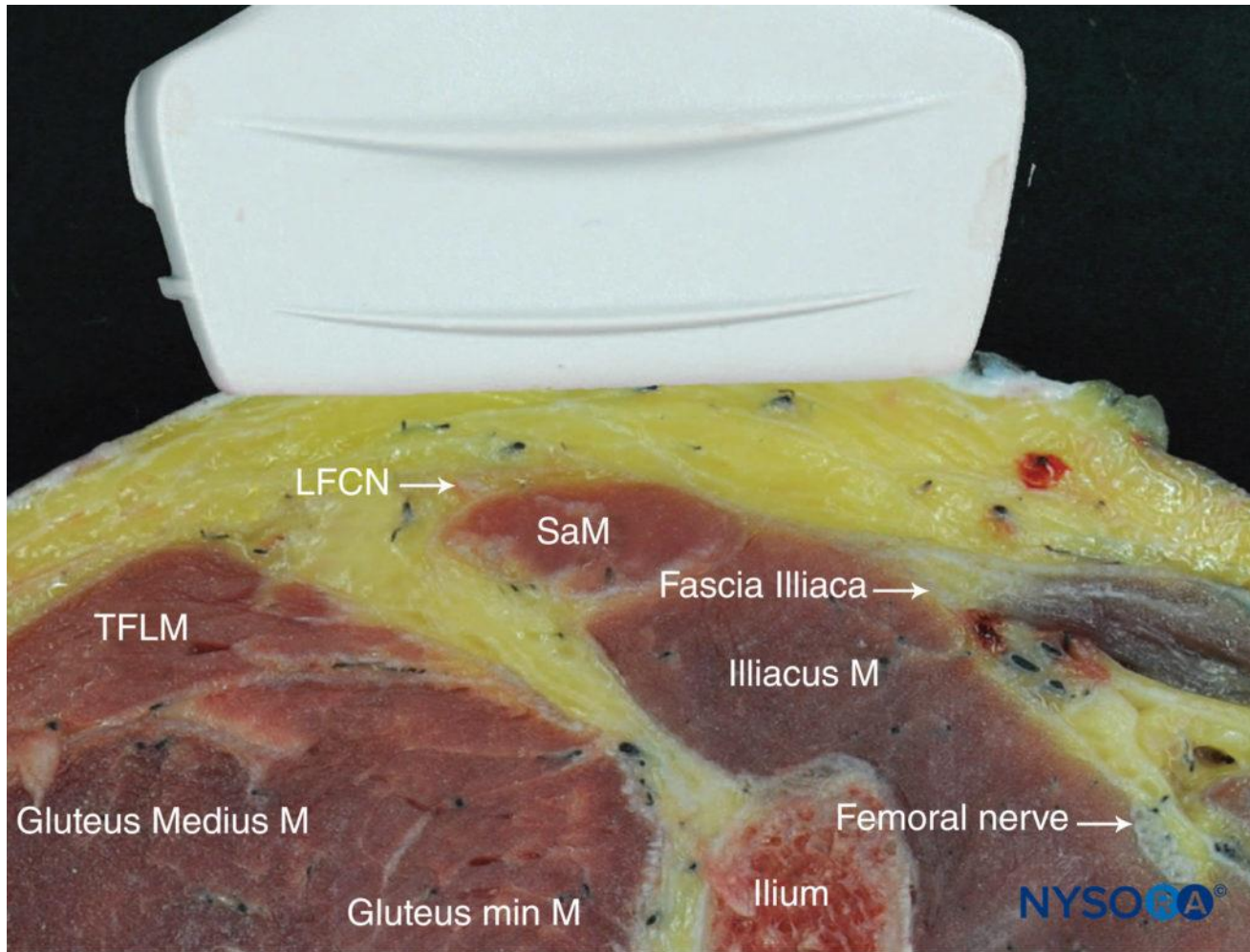


NYSOCO®

LE 22 ÉME CONGRÈS NATIONAL DE LA SAARSIU ALger, Le 15, 16 et
le 17 Décembre 2022

- **Analgésie dans la région antérolatérale de la cuisse.**
- **Grande variation territoire d'innervation sensitive entre les individus**





TECHNIQUE DU Bloc du NCLC

- **INDICATIONS:** analgésie de la face antérolatérale de la cuisse
- **SONDE:** linéaire
- **POSITION:** DD
- **AIGUILLE:** 22 G 5-10cm
- **VOLUME:**10 – 15 ml

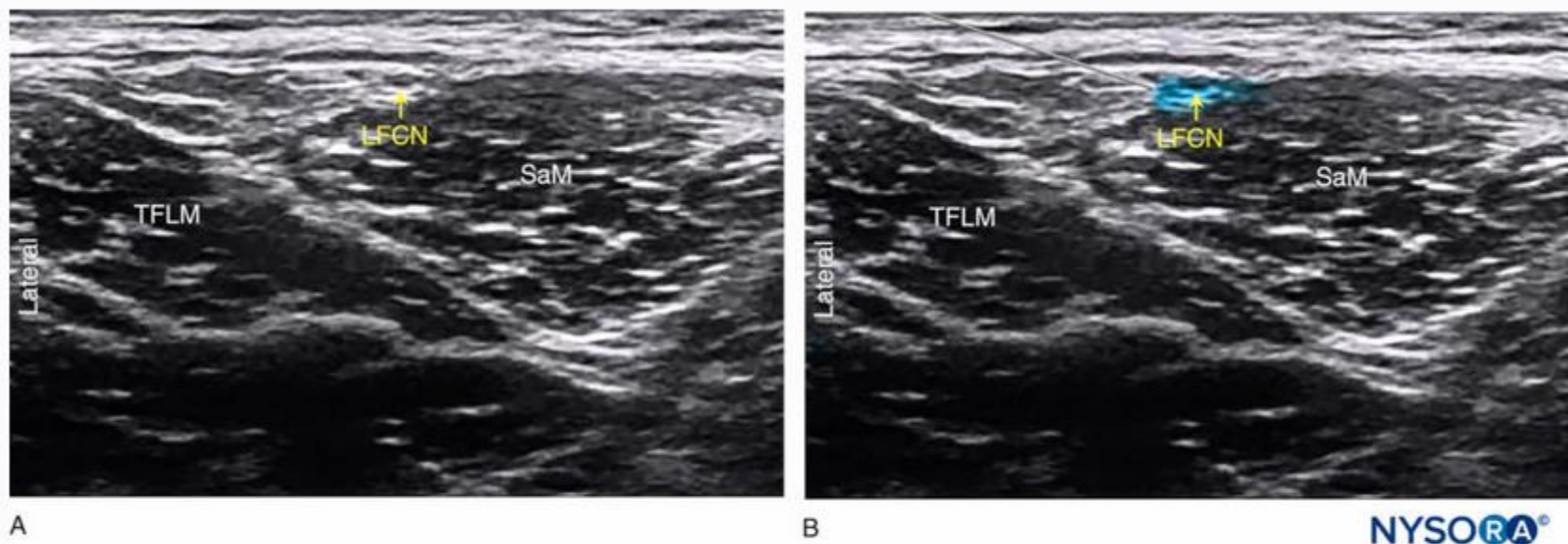
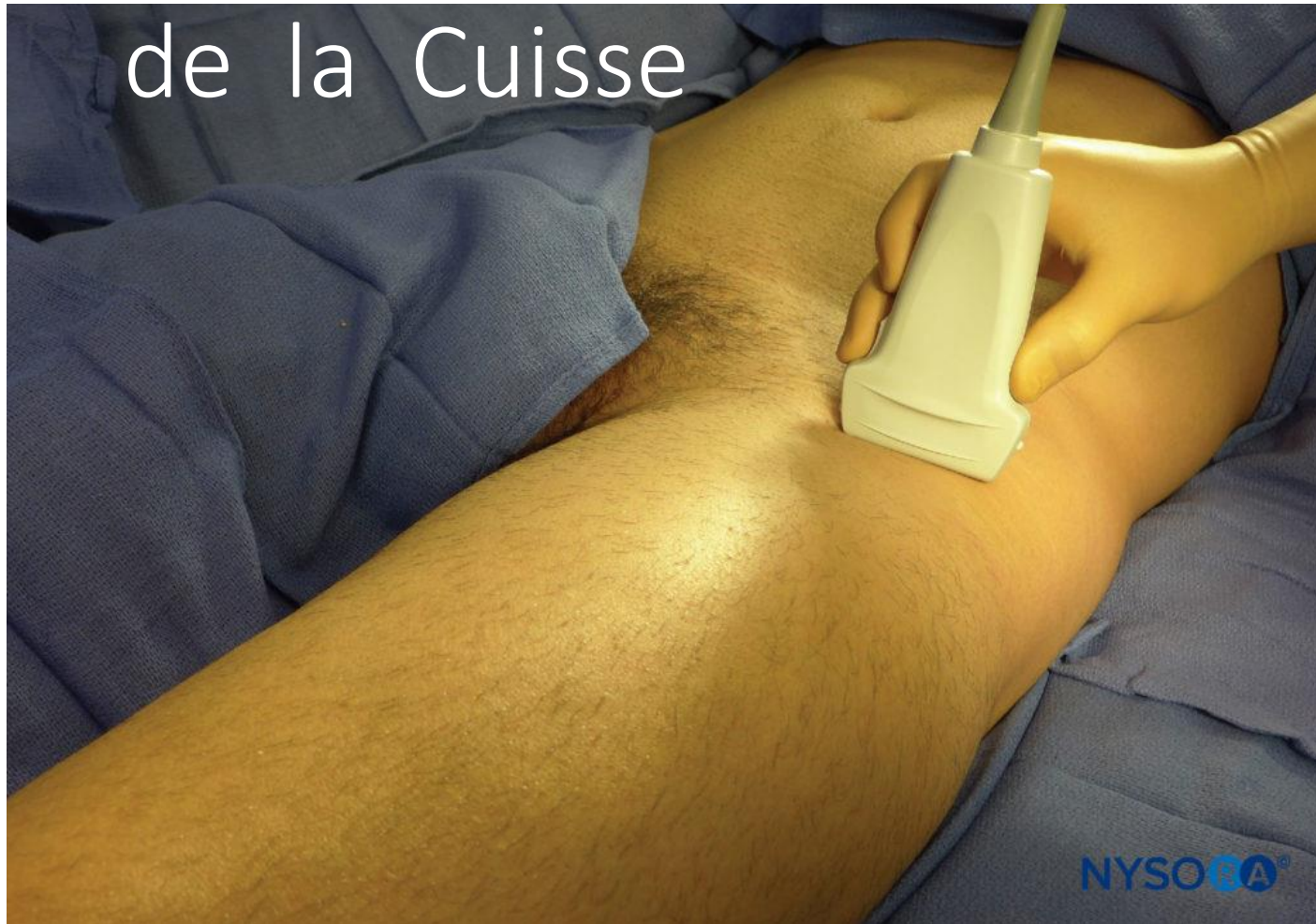

FIGURE 4. (A) Ultrasound anatomy of the lateral femoral cutaneous nerve (LFCN). **(B)** Simulated needle path and local anesthetic spread (blue-shaded area) to anesthetize the LFCN.

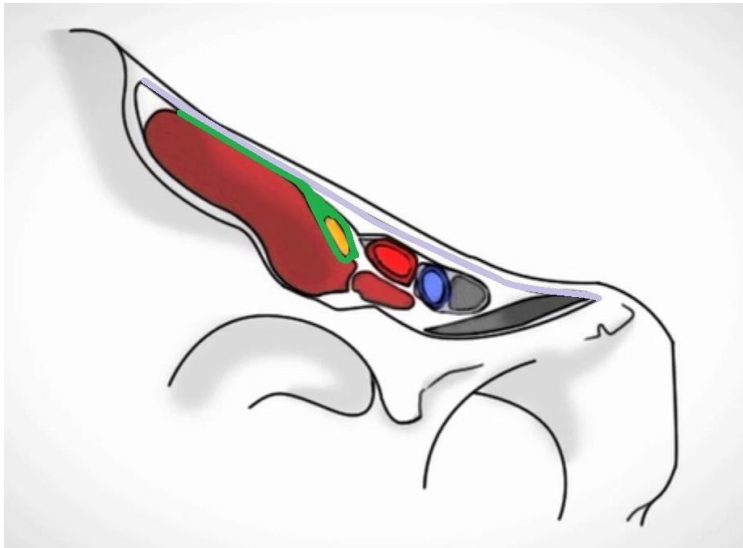
APPROCHE DU Nerf Cutané Latéral

de la Cuisse




NYSOBA®

Bloc Ilio - Fascial



CLINICAL INVESTIGATION



Pain Management with Early Regional Anesthesia in Geriatric Hip Fracture Patients

John M. Garlich, MD,MHDS, Amit Pujari, BS,* Zachary Moak, MD,† Eytan Debbi, MD,**

JAGS 00:1-8, 2020
© 2020 The American Geriatrics Society

0002-8614/20/\$15.00

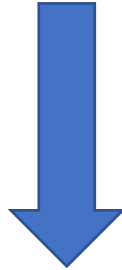CONCLUSION: FIBs reduce preoperative opioid intake and have low rates of opioid-related adverse events in geriatric hip fracture patients.

LEVEL OF EVIDENCE: The level of evidence was II. *J Am Geriatr Soc* 00:1-8, 2020.

JAGS 00:1-8, 2020
© 2020 The American Geriatrics Society

0002-8614/20/\$15.00

Bloc Ilio – Fascial : DIFFUSION



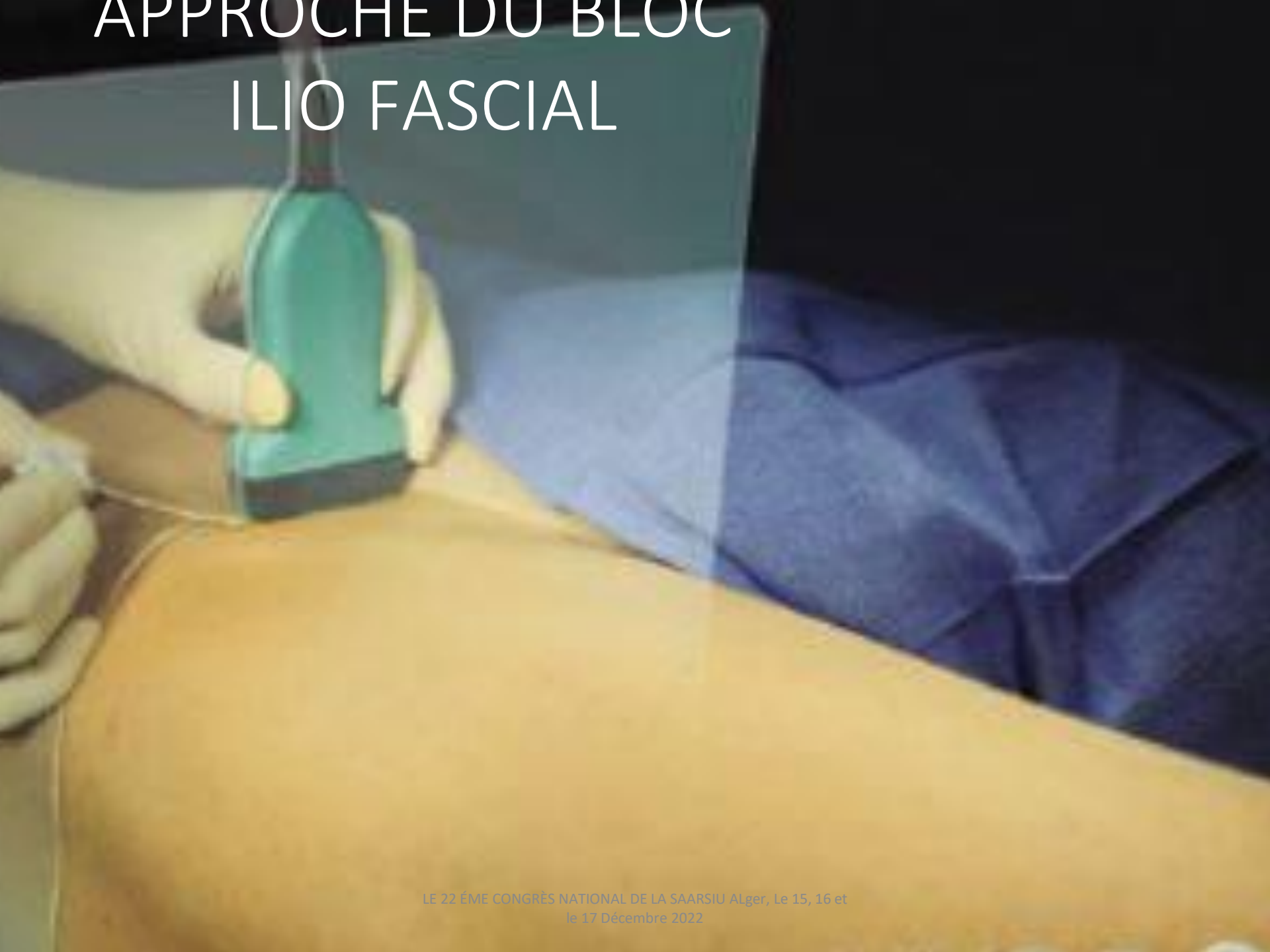1. Nerf Cutané Latéral de la Cuisse
2. Nerf Fémoral
3. Plexus Lombaire



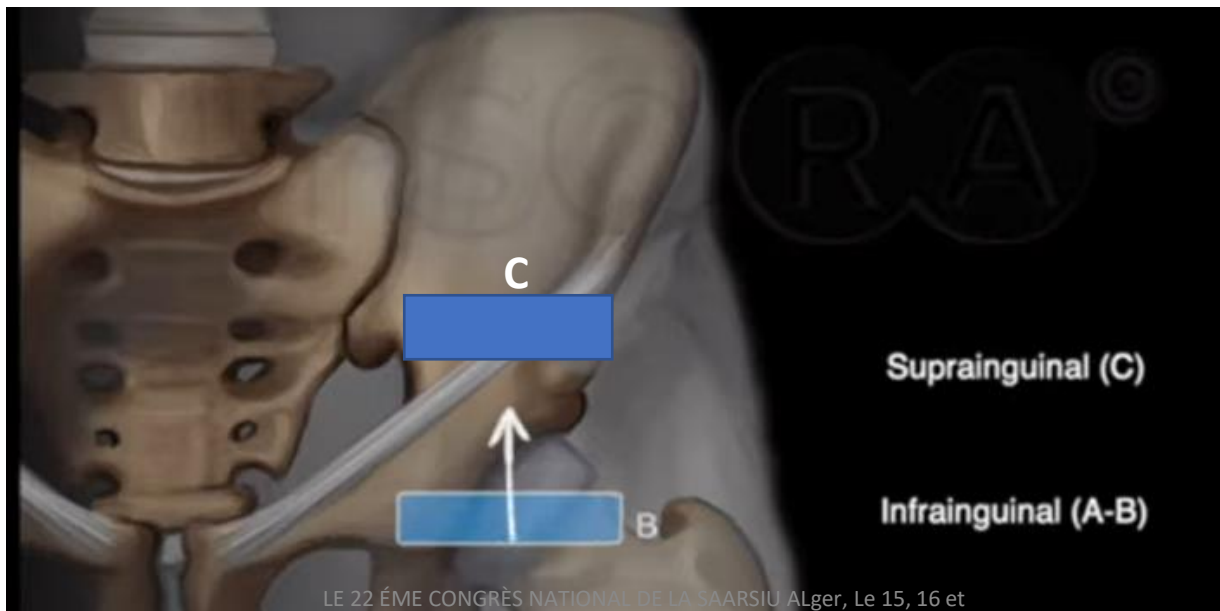
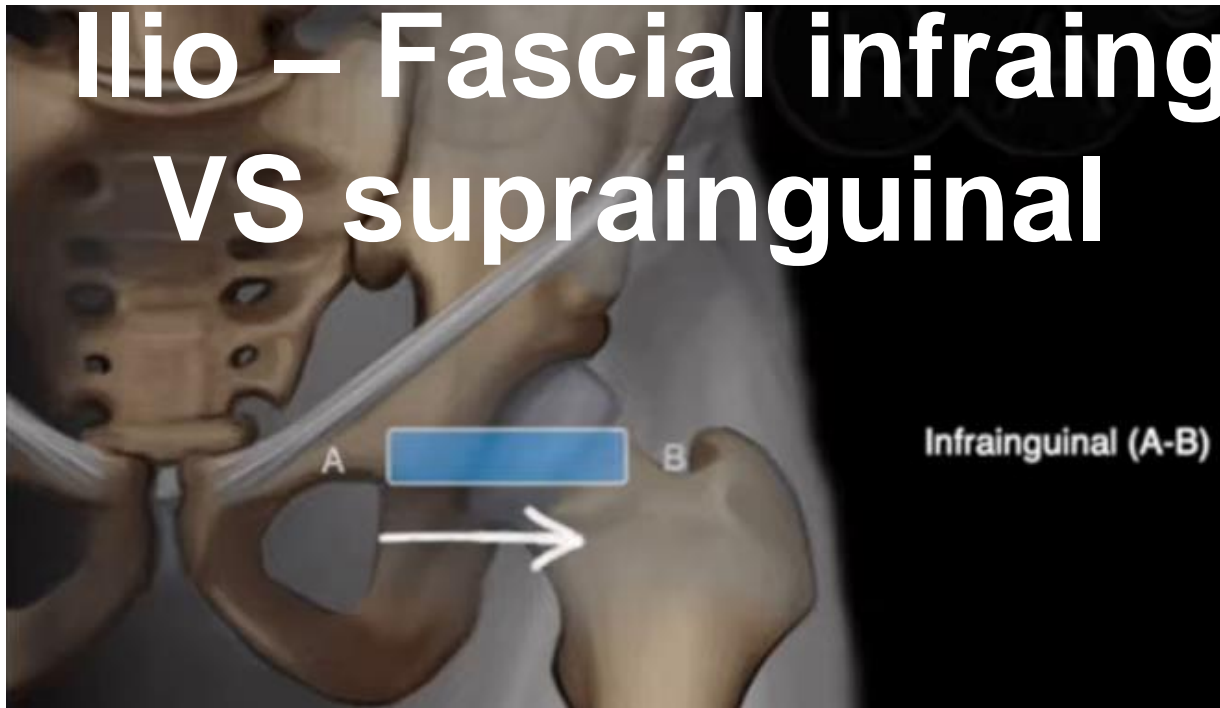
BIF = Alternative

- Bloc Nerf Fémoral + NCLC
- et Bloc du Plexus Lombaire

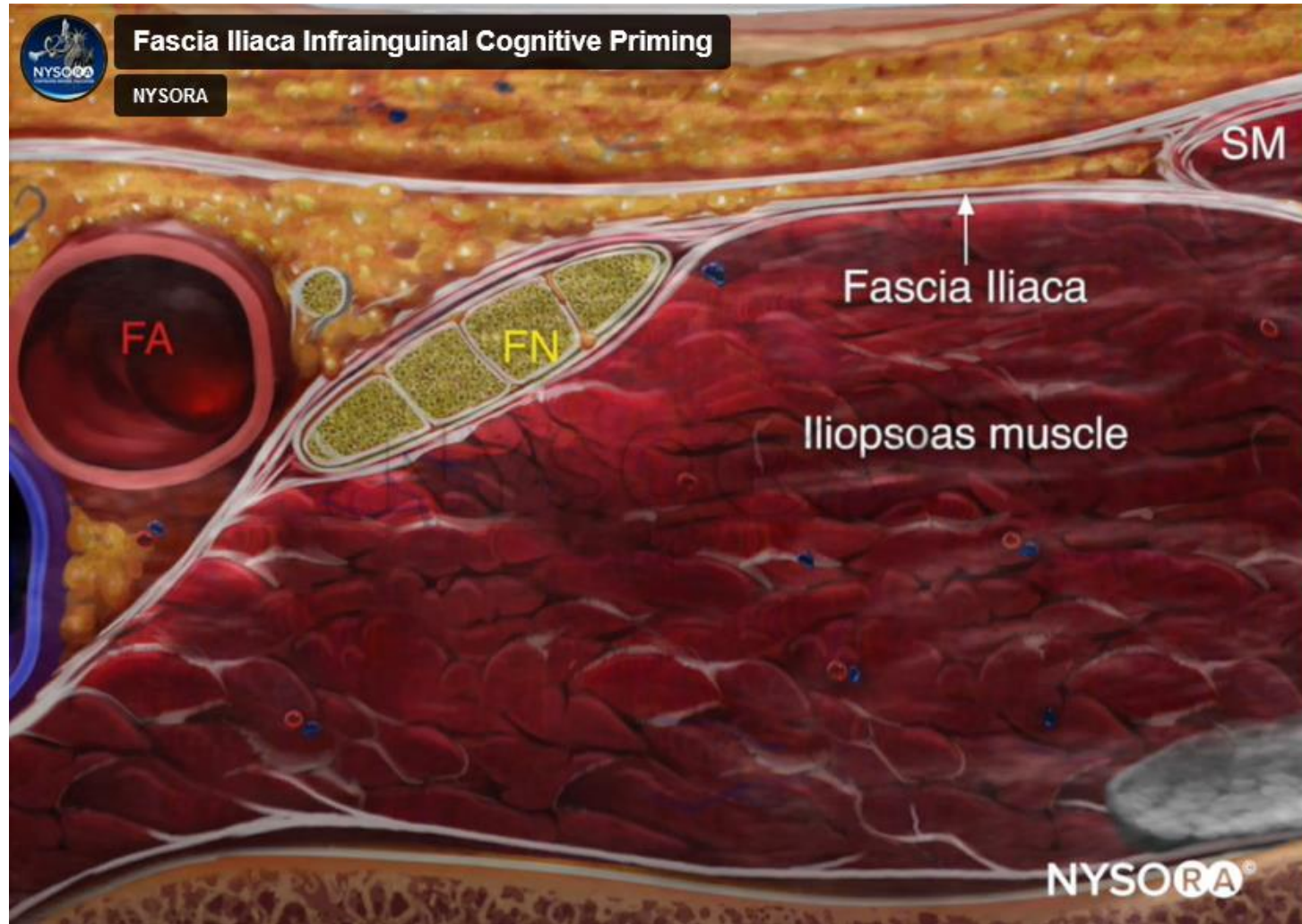
APPROCHE DU BLOC ILIO FASCIAL



Ilio – Fascial infrainguinal VS suprainguinal



SONOANATOMIE Bloc Ilio – Fascial infrainguinal



SONOANATOMIE Bloc Ilio – Fascial infrainguinal

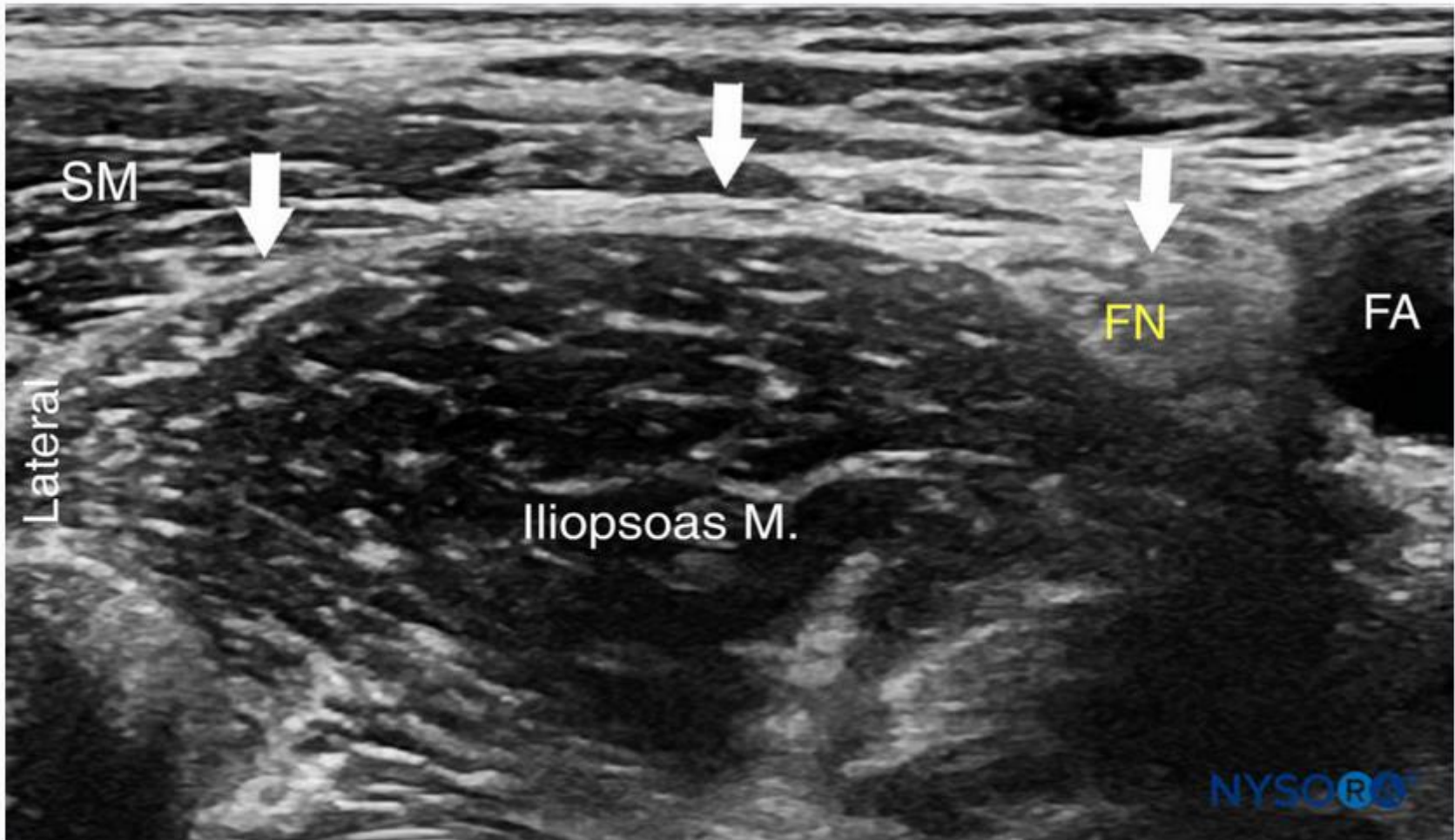
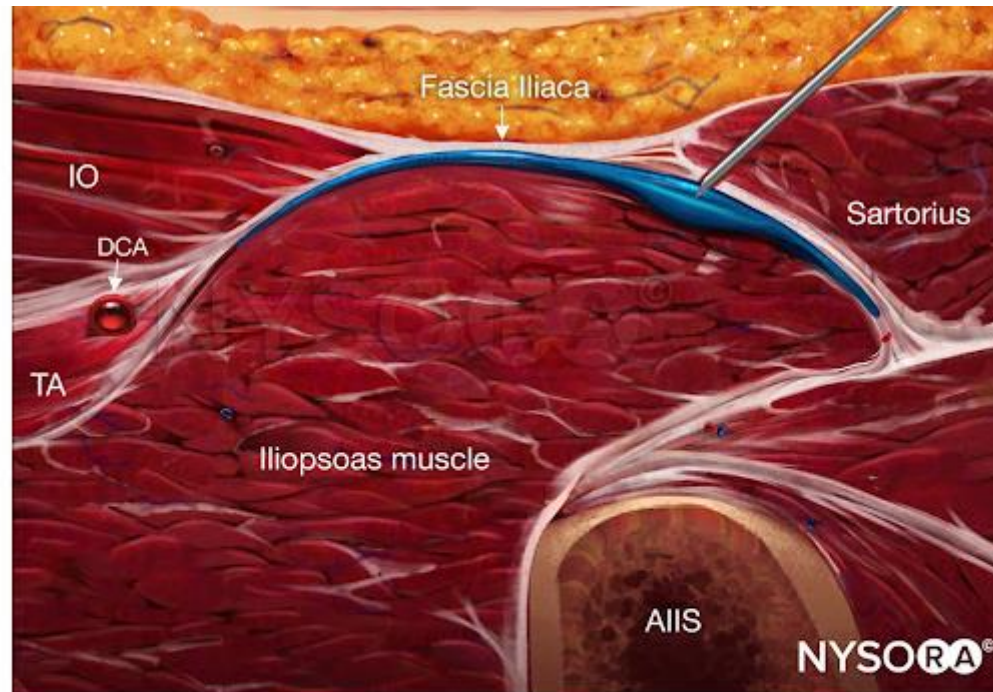


FIGURE 4. Ultrasound image of the fascia iliaca (white line and arrows) at the level of the inguinal ligament. The femoral nerve (FN) and femoral artery (FA) are visualized on the medial side and the sartorius muscle (SM) on the lateral side.

TECHNIQUE DU BLOC ILIO FASCIAL

- **INDICATIONS: analgésie des # hanche**
- **SONDE: linéaire**
- **POSITION: DD**
- **AIGUILLE: 22 G 5-10cm**
- **VOLUME: 20 – 40 ml**

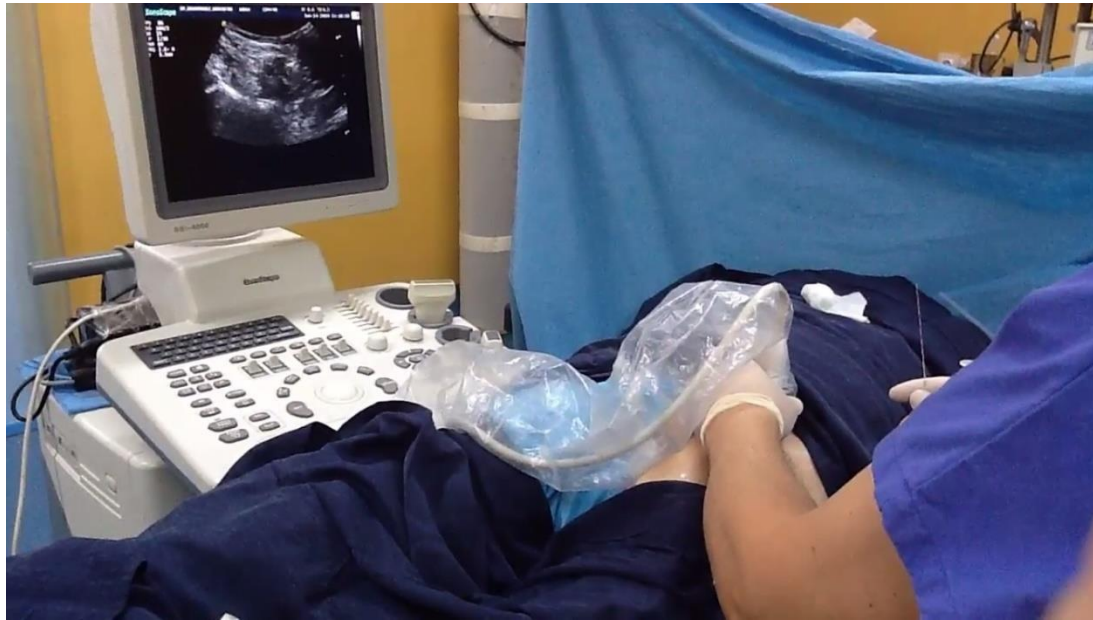SONOANATOMIE Bloc Ilio – Fascial suprainguinal



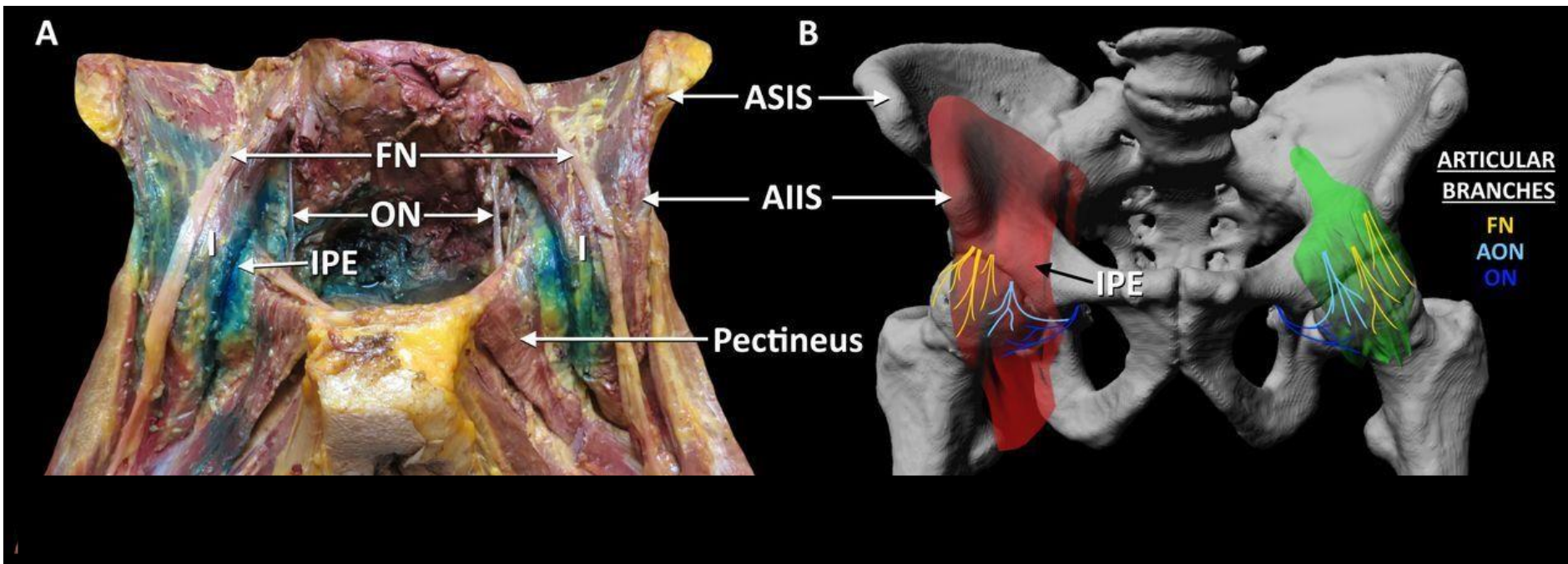
**From the Compendium of Regional Anesthesia: Reverse
Ultrasound Anatomy for a suprainguinal fascia iliaca block with
needle insertion in-plane and local anesthetic spread (blue). FN,
femoral nerve; IO, internal oblique; TA, transversus abdominis;
AIIS, anterior inferior iliac spine; DCA, deep circumflex artery.**

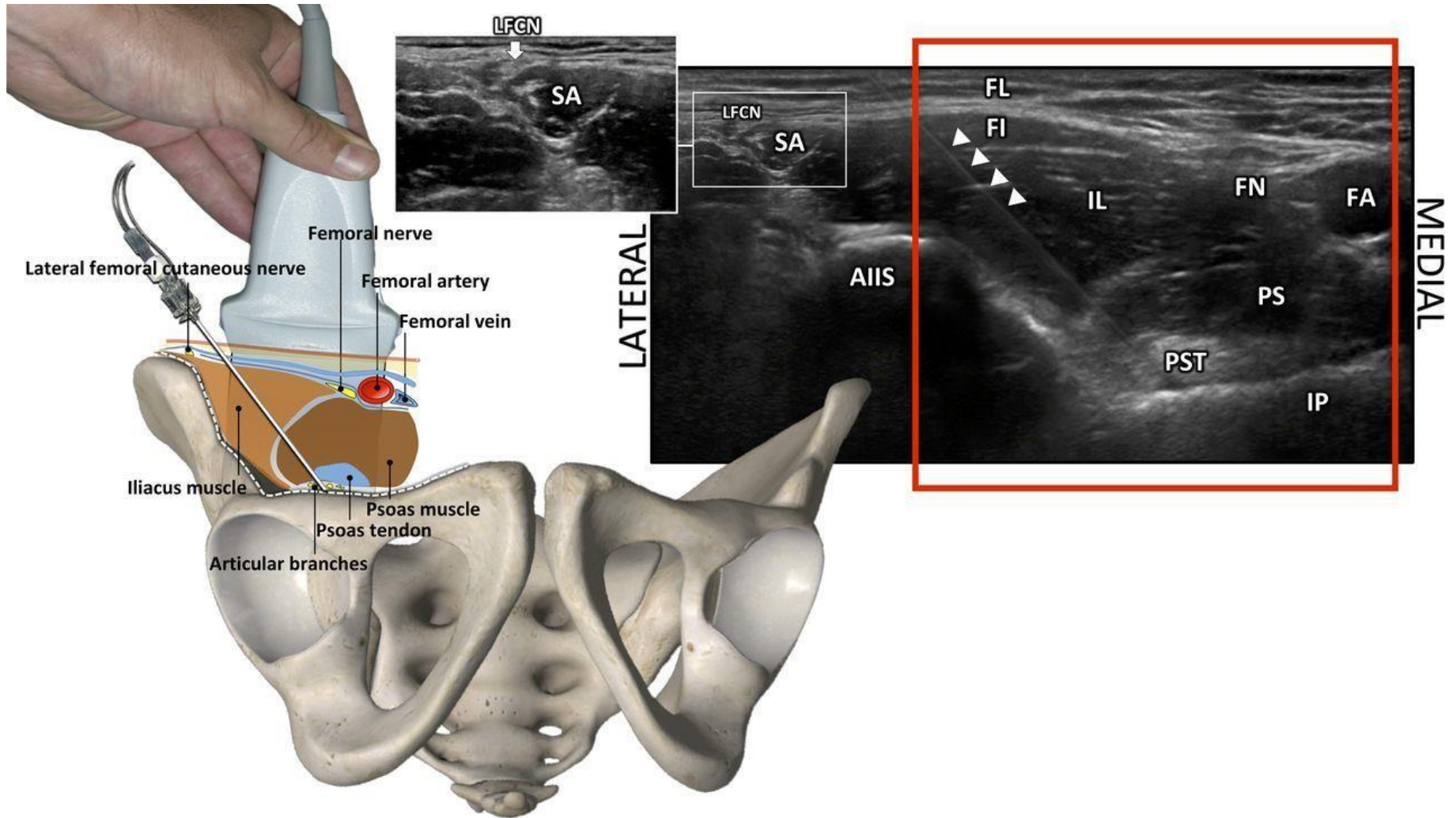
PENG BLOCK

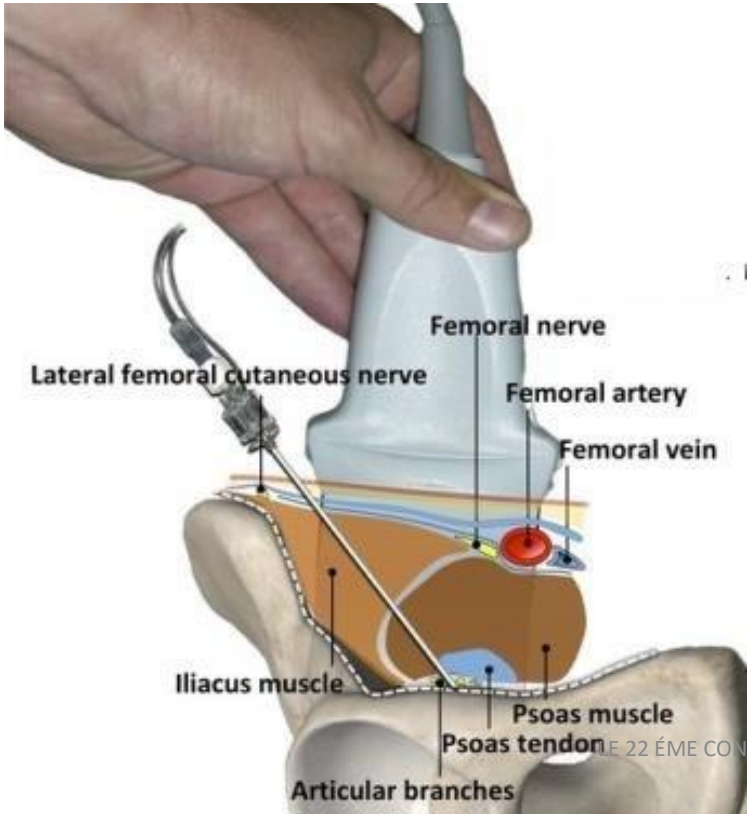
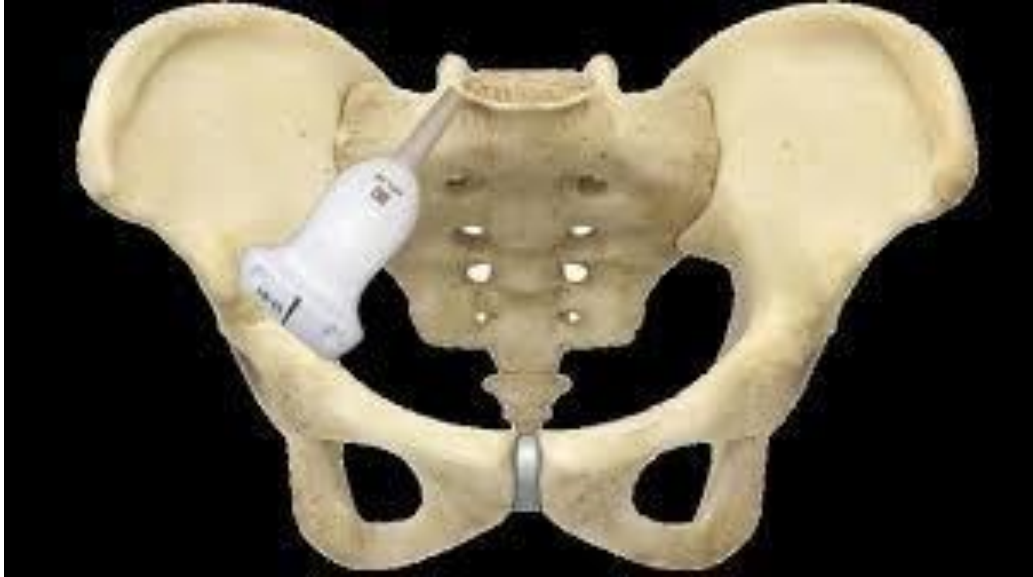PERICAPSULAR NERVE GROUP BLOCK



BASES ANATOMIQUES







SonoScape

DR_BOUARROUDJ_NOREDDINE

admin

C344/40

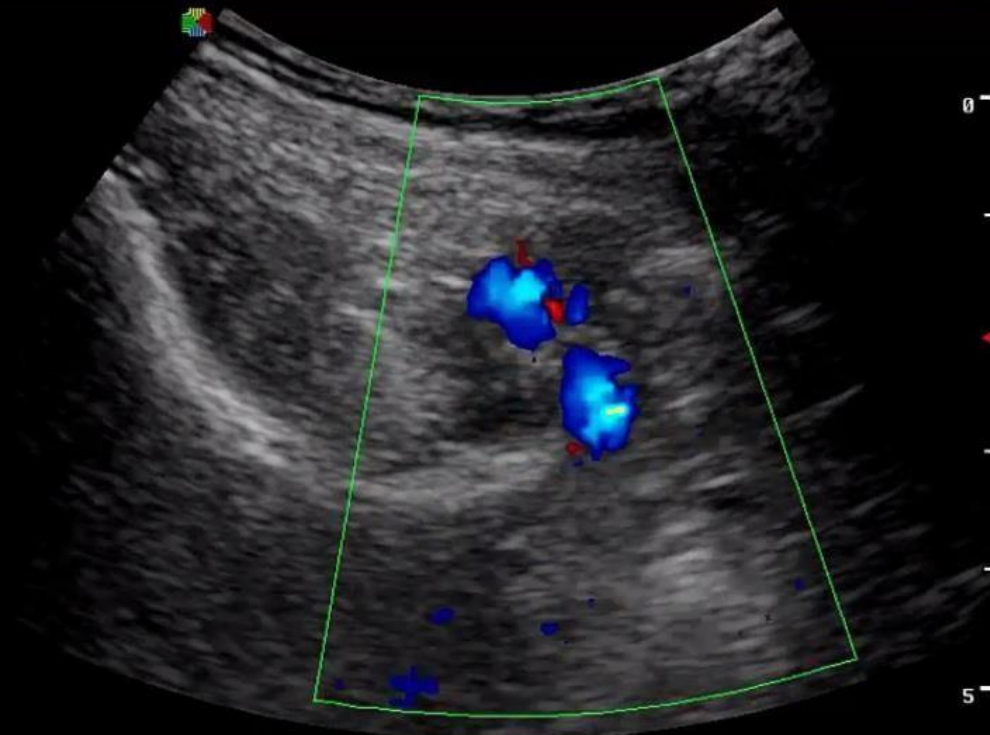
MI 0.7 TIS 0.7

Jun-24-2019 14:20:20



FPS 27
D/G 160/2
GN 25
I/P 2/30
PWR 60
FRQ 2.8- 6
D 5.5cm

PRF 0.8
WF 60
GN 15
C/P 3/60
PWR 70
FRQ 2.4



SONOANATOMIE



SonoScape

DR_BOUARROUDJ_NOREDDINE

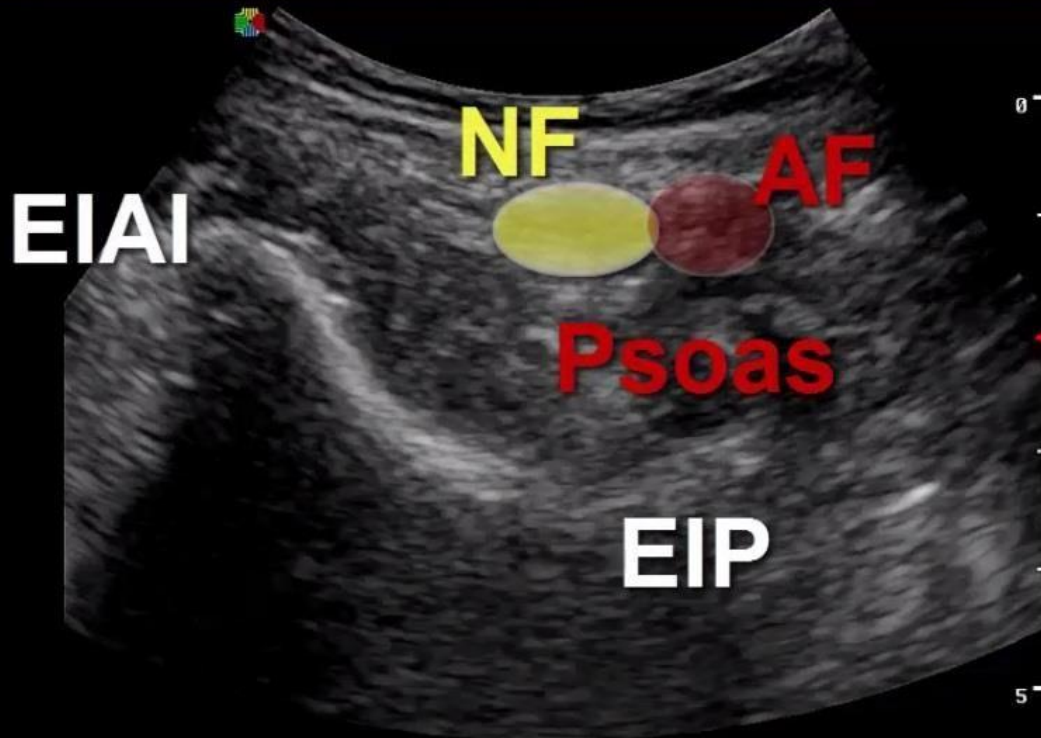
admin

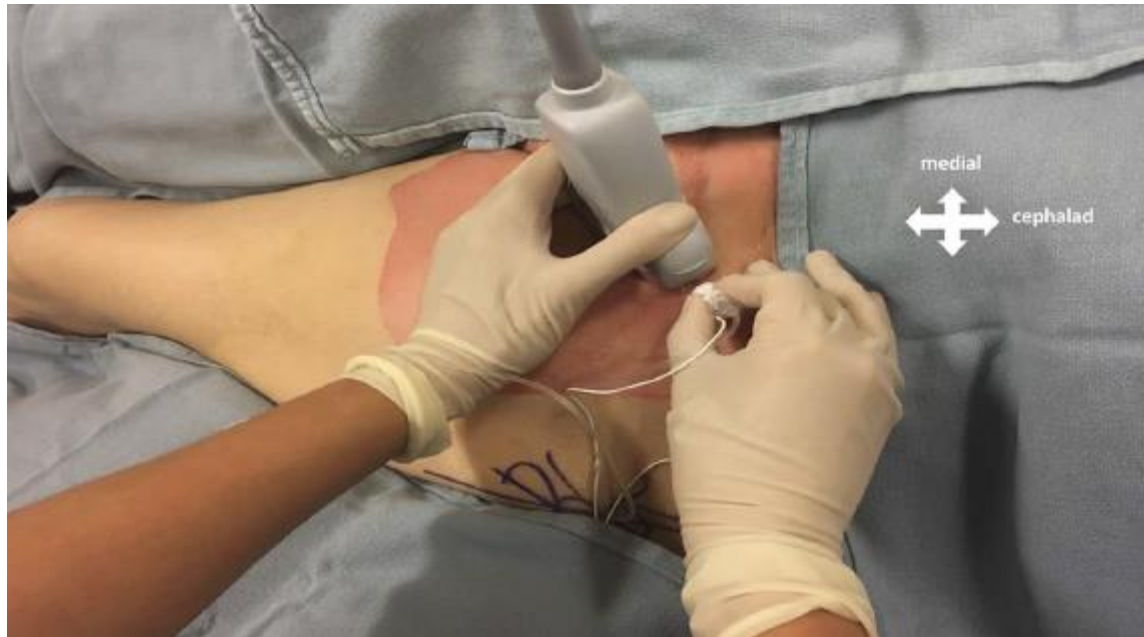C344/40

MI 0.6 TIS 0.2

Jun-24-2019 14:21:09

FPS 83
D/G 160/2
GN 25
I/P 2/30
PWR 60
FRQ 2.8- 6
D 5.5cm





TECHNIQUE DU PENG BLOCK

- **INDICATIONS: analgésie des # hanche**
- **SONDE: Convexe**
- **POSITION: DD**
- **AIGUILLE: 22 G 10-15cm**
- **VOLUME: 30 ml**

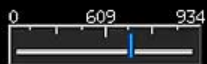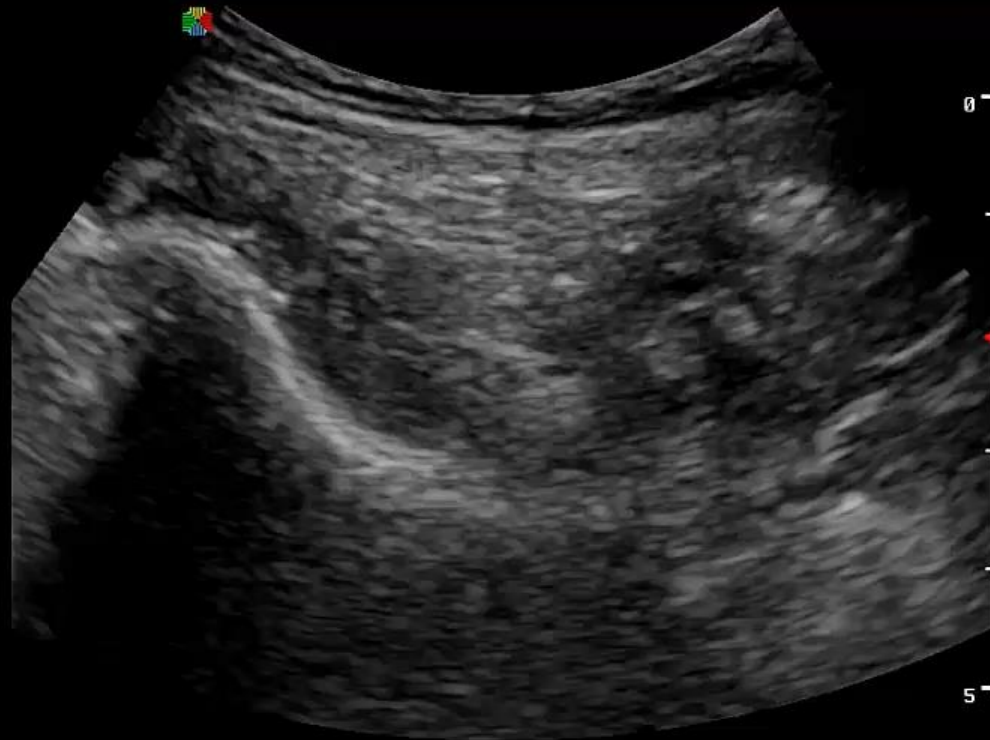DR_BOUARROUDJ_NOREDDINE admin

C344/40

MI 0.6 TIS 0.2

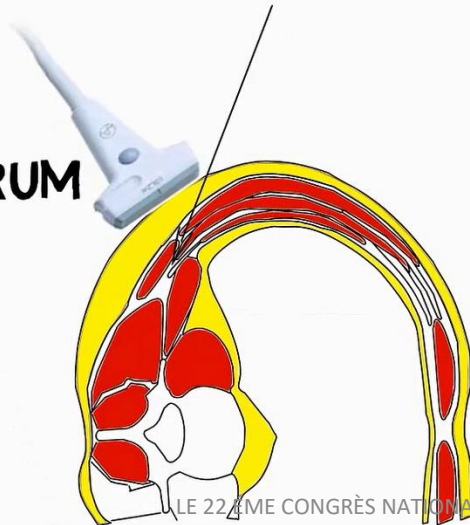
Jun-24-2019 14:21:09

FPS 83
D/G 160/2
GN 25
I/P 2/30
PWR 60
FRQ 2.8- 6
D 5.5cm



BLOC DU CARRE DES LOMBES (QLB BLOCK).

**LUMBORUM
BLOCK**





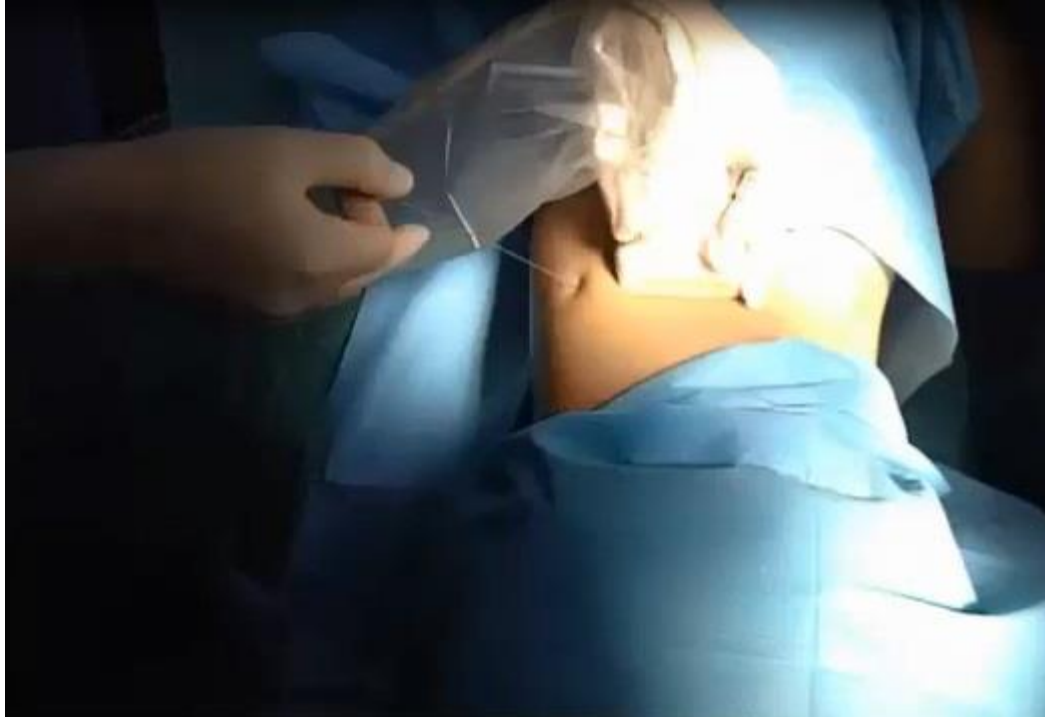Quadratus lumborum block provides improved immediate postoperative analgesia and decreased opioid use compared with a multimodal pain regimen following hip arthroscopy

Christopher L. McCrum¹, Bruce Ben-David², Jason J. Shin³ and Vonda J. Wright^{4*}

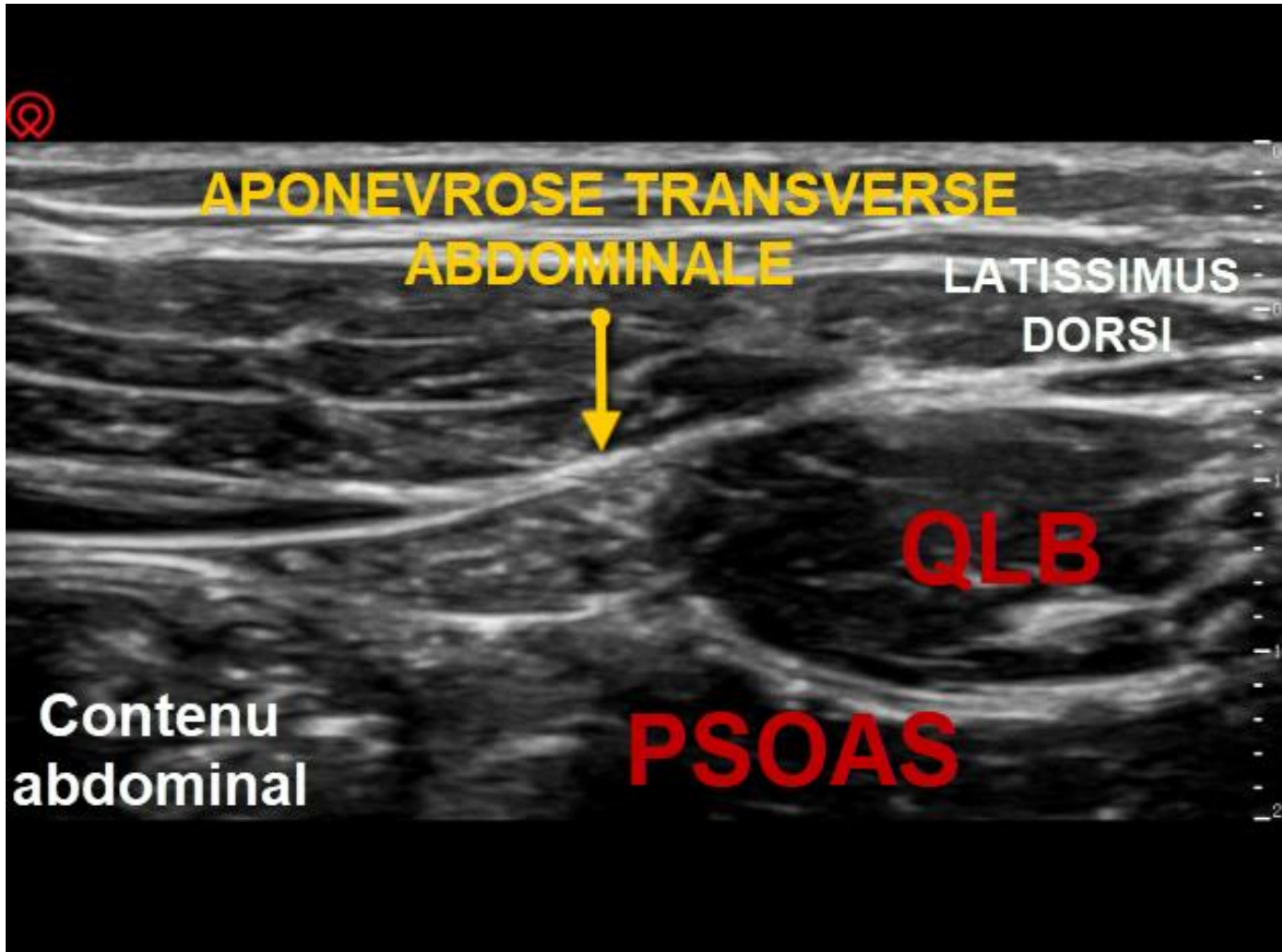
CONCLUSION

Hip arthroscopy patients who received a preoperative QL block had less pain and a lower opioid requirement in PACU than those who did not receive a block. These outcome improvements notwithstanding, there was no significant difference between groups in time to discharge.

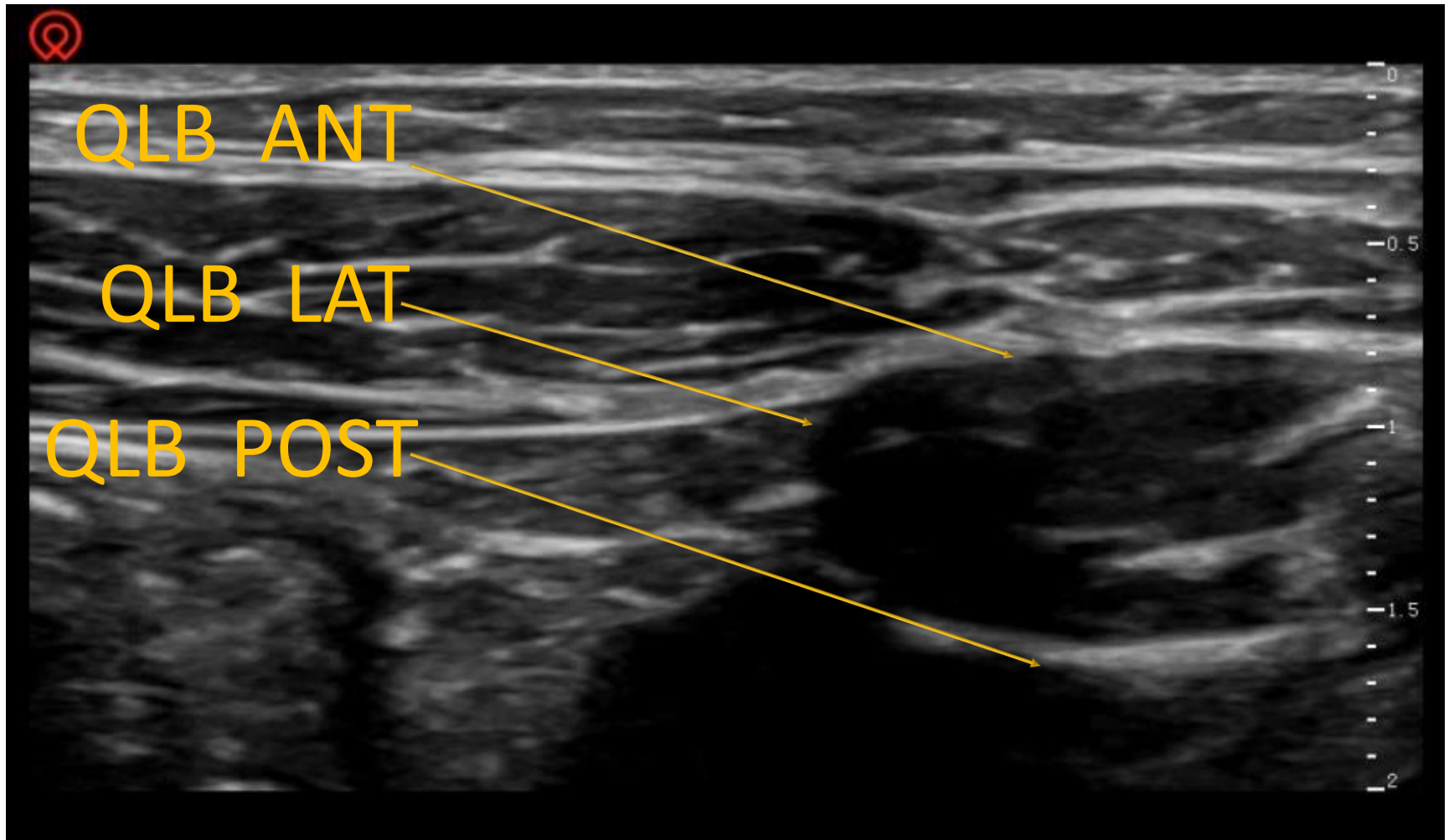
APPROCHE DU QLB BLOCK



SONOANATOMIE



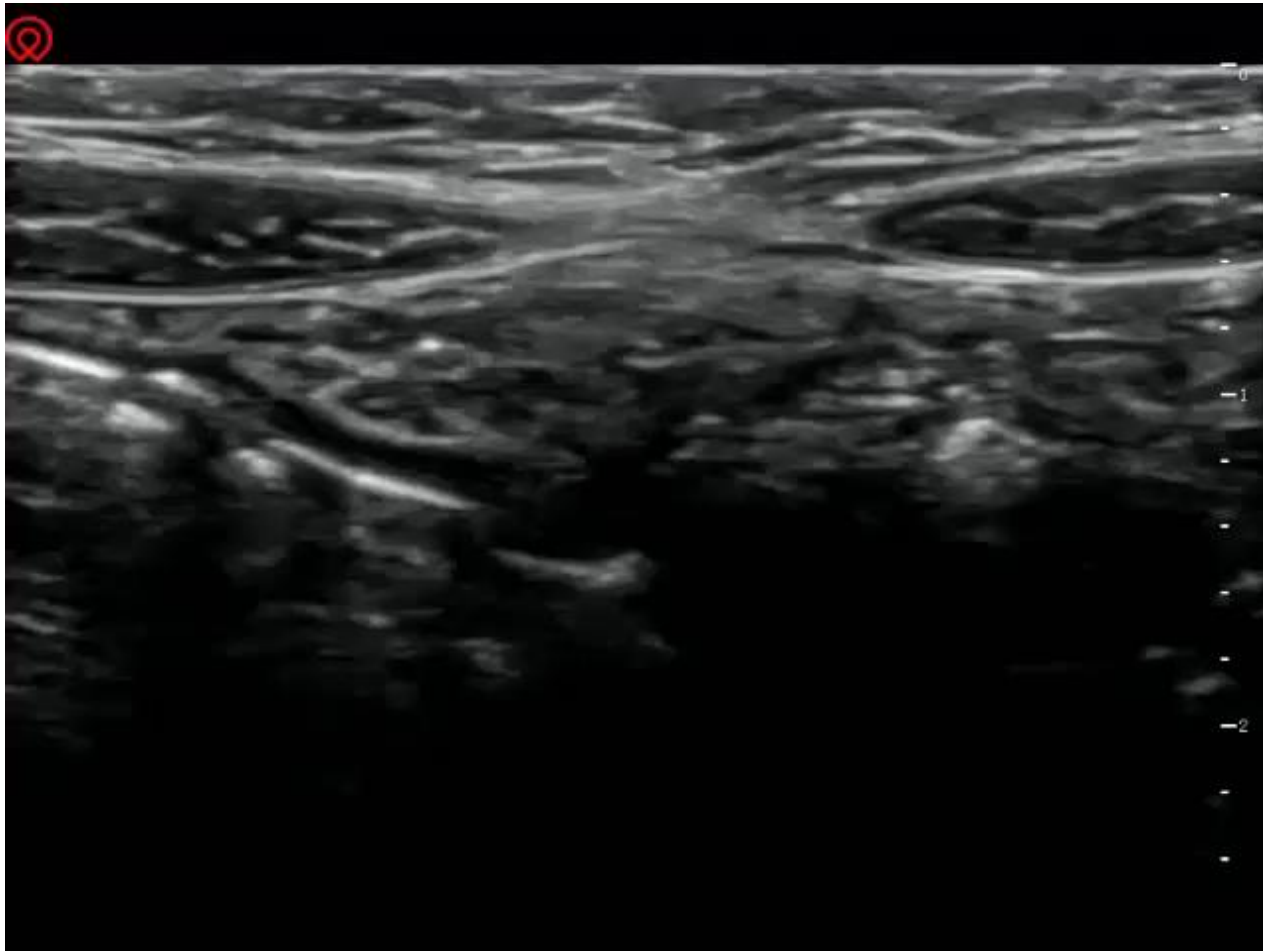
QLB ANT, QLB LAT ET QLB POST



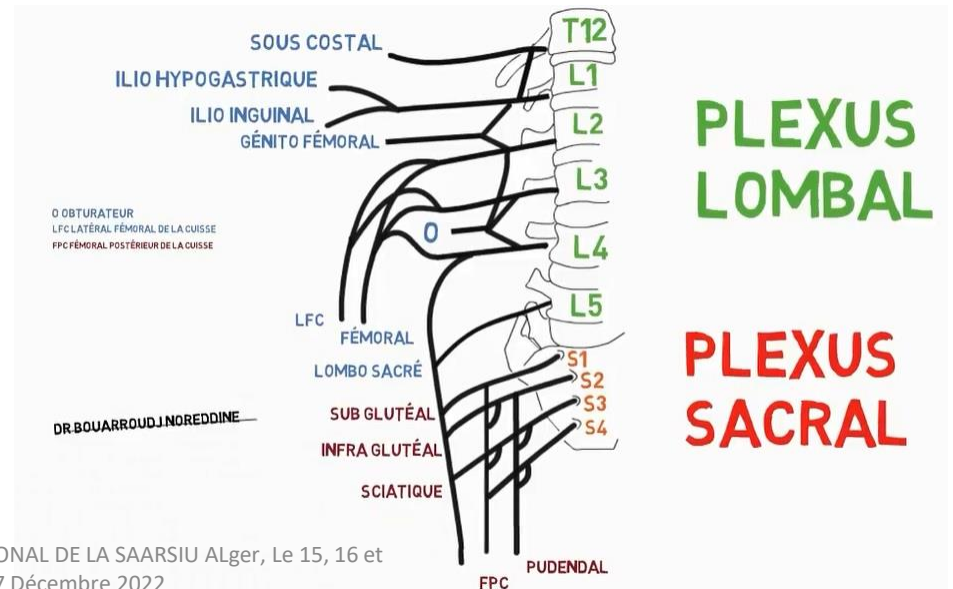
TECHNIQUE DU QLB BLOCK

- **SONDE: linéaire ou convexe**
- **POSITION: DL**
- **AIGUILLE: 22 G 10-15 cm**
- **VOLUME: 20 – 30 ml**

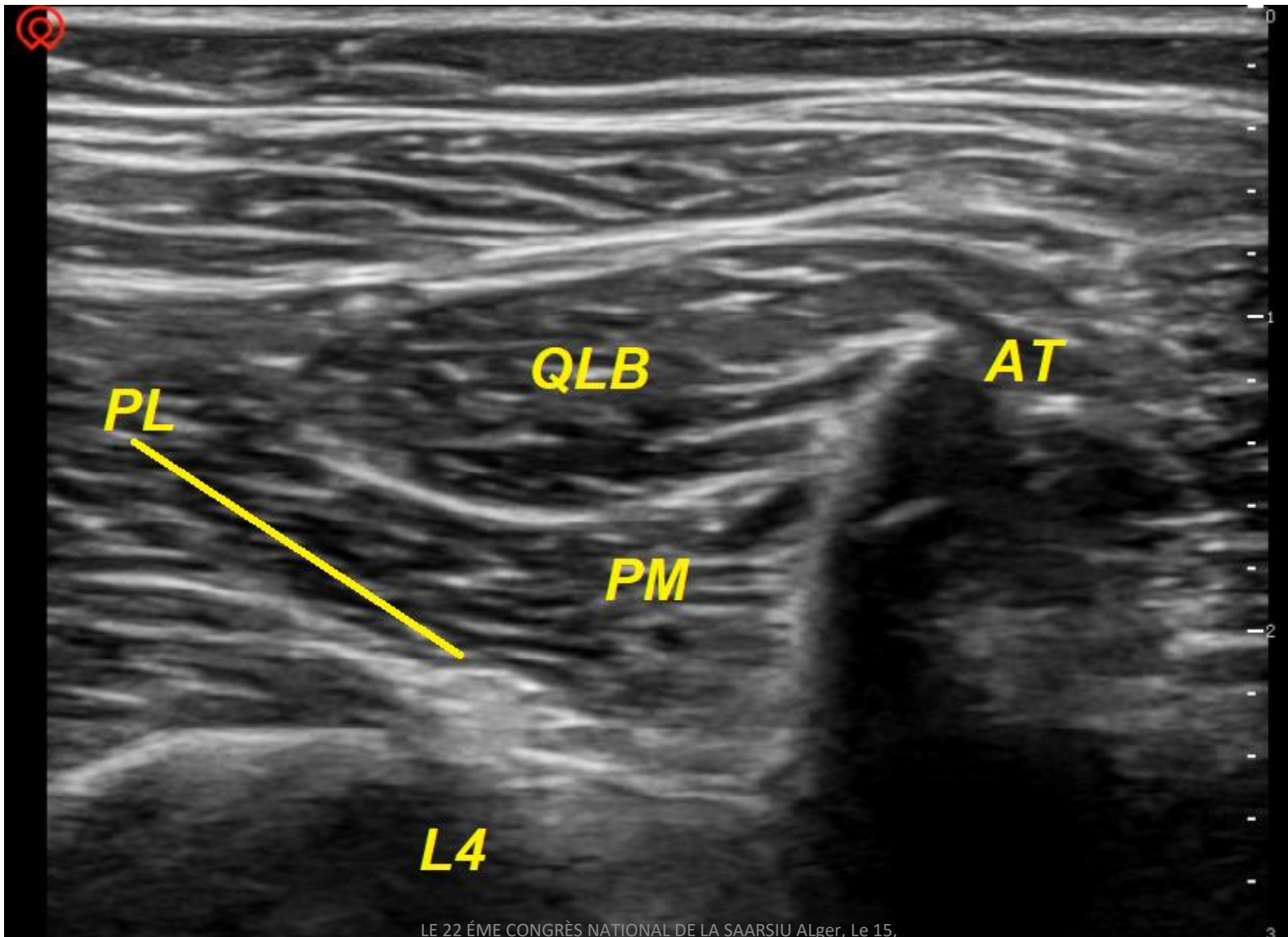
QLB POST



Bloc du PLEXUS LOMBAL



SONOANATOMIE



TECHNIQUE DU BLOC DU PLEXUS LOMBAIRE

- **SONDE: CONVEXE**
- **POSITION: DL**
- **AIGUILLE: 22 G 10-15cm**
- **VOLUME: 20 – 30 ml**

APPROCHE DU BLOC DU PLEXUS LOMBAIRE

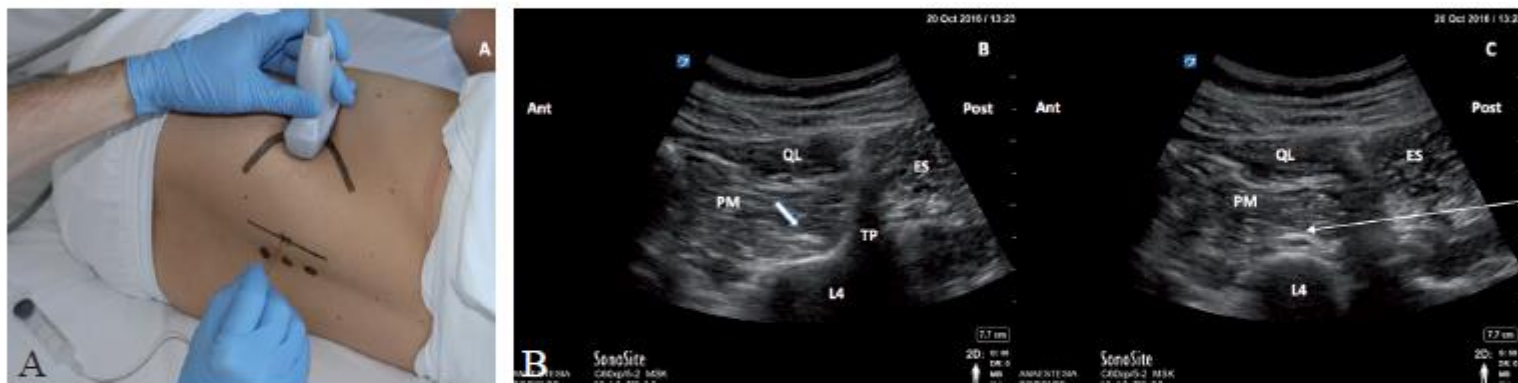

Figure 1.—A) The patient (model photo) is placed lateral decubitus with the side to be anaesthetised facing upwards. The spinous processes of L3-L5, the iliac crest and the lower border of the rib cage are marked on the skin. The needle is inserted 3-4 cm lateral (marked parasagittal line) to the spinous process L4. The curvilinear transducer is placed in the flank just cranial to the iliac crest approximately in the posterior axillary line. B) Ultrasound image of the Shamrock sign at the level of the vertebral body of L4. The *psaos major* (PM), *quadratus lumborum* (QL) and *erector spinae* (ES) muscles are the three leaves of the Shamrock. The transverse process (TP) is the stem of the trefoil. The white arrow points at the hyperechoic lumbar plexus within the PM. The ultrasound beam is directed towards the flat middle part of the vertebral body L4.³⁰ C: contact between the needle tip and the TP during needle insertion is avoided by tilting the probe beam caudad until the TP disappears from the ultrasound image and the shape of the vertebral body is visualised as a “bulging edge”.³⁰ The needle (thin white arrow) is inserted in a posterior (Post) to anterior (Ant) direction and advanced in-plane with the ultrasound beam. The endpoint of injection is just lateral to the lumbar plexus.

THE SHAMROCK METHOD FOR LPB

20 Oct 2016 / 13:22



SonoSite

C60xp/5-2 MSK LE 22 ÉME CONGRÈS NATIONAL DE LA SAARSIU ALger, Le 15,
16 et le 17 Décembre 2022

ANAESTHESIA
ROSKILDE

7.7 cm

2D: G: 50
DR: 0
MB
THI





Contents lists available at [ScienceDirect](https://www.sciencedirect.com)

Journal of Clinical Anesthesia

journal homepage: www.elsevier.com/locate/jclinane



Original contribution

Lumbar plexus block versus suprainguinal fascia iliaca block for total hip arthroplasty: A single-blinded, randomized trial



Daniela Bravo (MD) (Assistant Professor)^{a,*}, Sebastián Layera (MD) (Clinical Instructor)^a, Julián Aliste (MD) (Assistant Professor)^a, Álvaro Jara (MD) (Clinical Instructor)^a, Diego Fernández (MD) (Clinical Instructor)^a, Cristián Barrientos (MD) (Assistant Professor)^b, Rodrigo Wulf (MD) (Clinical Instructor)^b, Gonzalo Muñoz (MD) (Resident)^a, Roderick J. Finlayson (MD, FRCPC) (Professor)^c, De Q. Tran (MD, FRCPC) (Professor)^d

Conclusions: For THA, no differences were found between LPB and SIFIB in terms of breakthrough morphine requirement and pain control. However, SIFIB resulted in a longer block and was associated with shorter time to readiness for discharge as well as decreased hospital stay.

* Corresponding author.

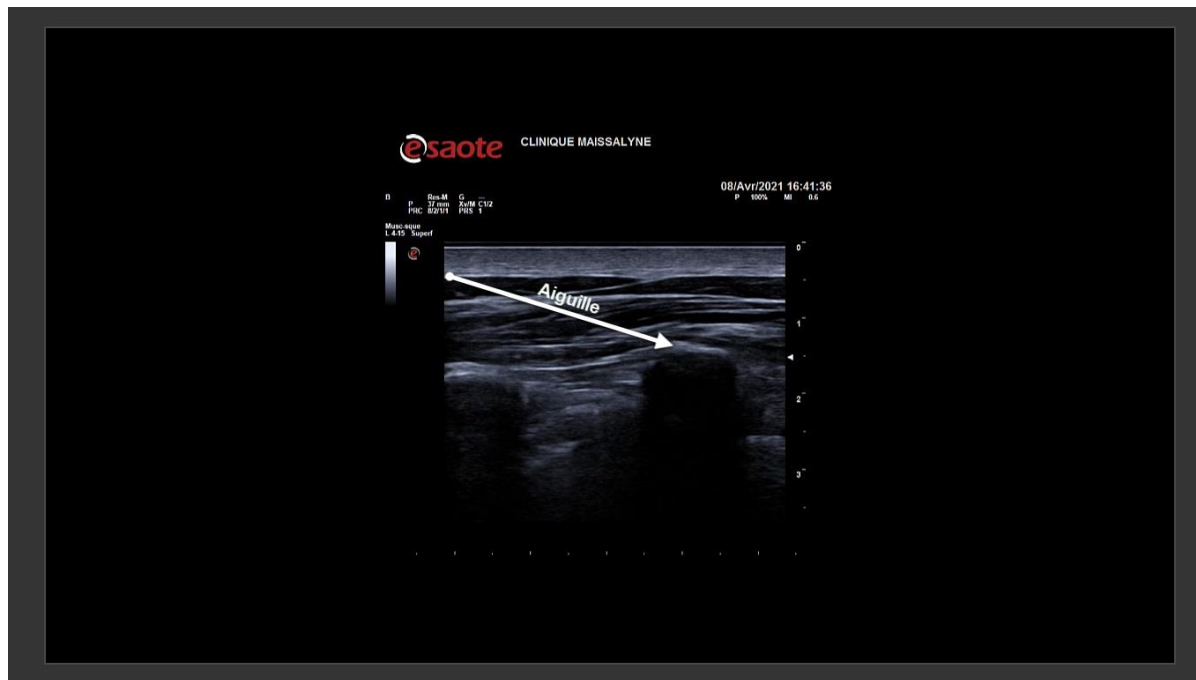
E-mail address: dbravoadvis@uchile.cl (D. Bravo).

<https://doi.org/10.1016/j.jclinane.2020.109907>

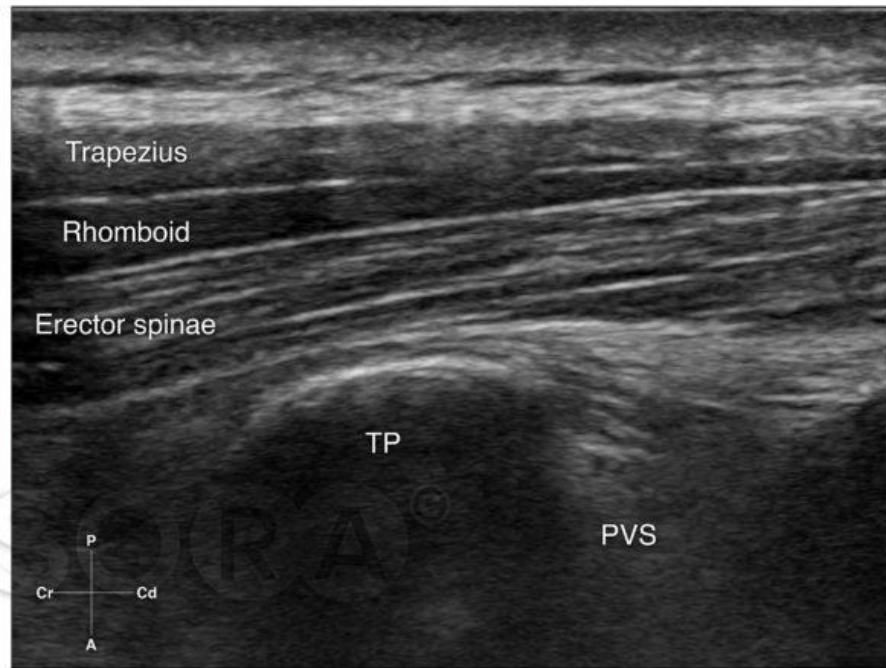
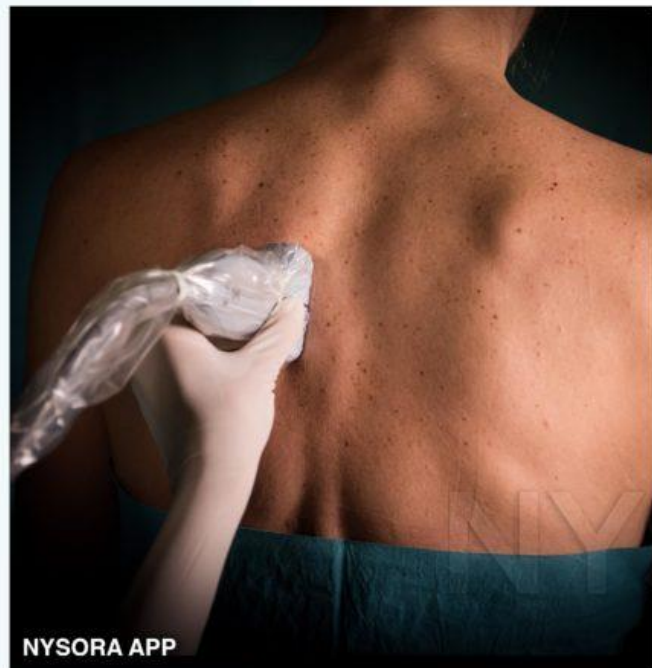
Received 3 March 2020; Received in revised form 30 April 2020; Accepted 21 May 2020

0952-8180/ © 2020 Elsevier Inc. All rights reserved.

Bloc des Erecteurs du Rachis ESP BLOCK

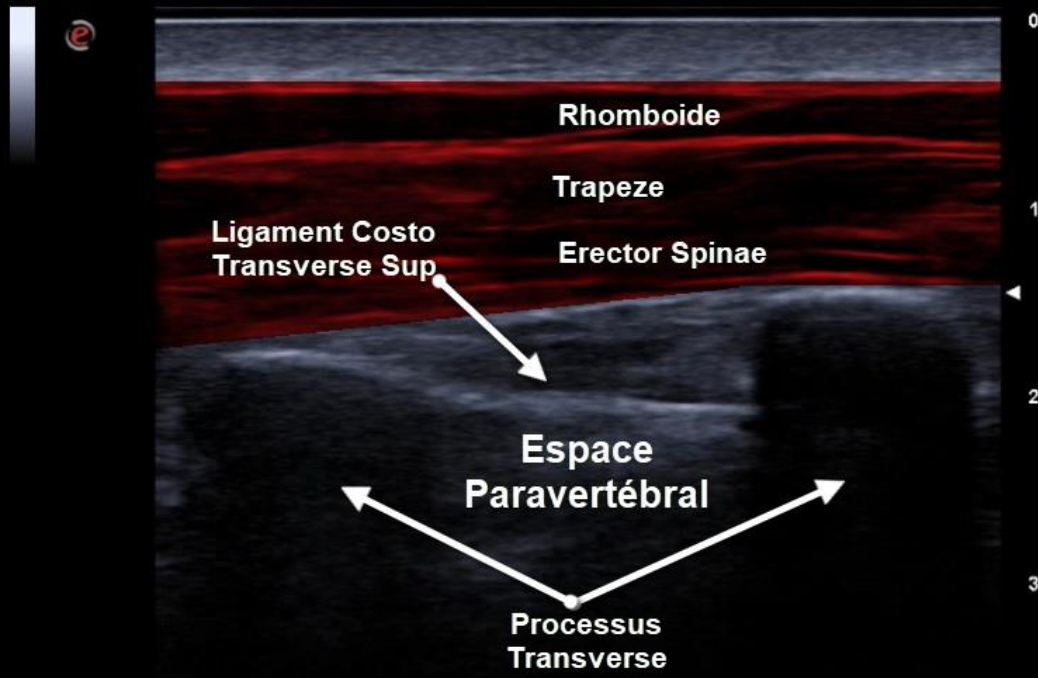


APPROCHE DE L'ESP BLOCK



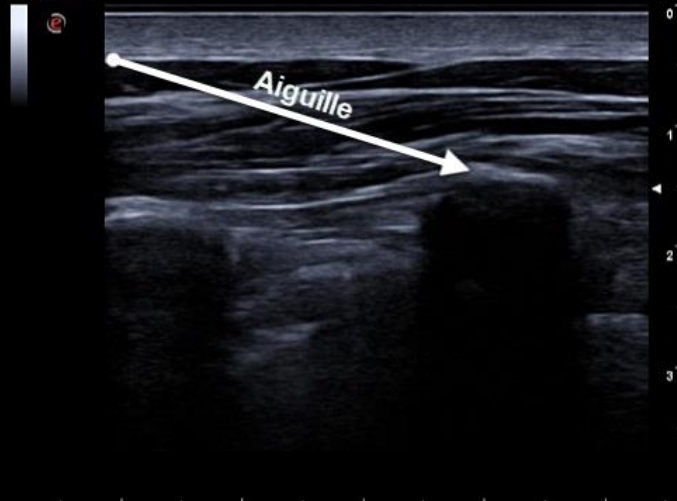
B Res-M G ---
P 37 mm Xv/M C1/2
PRC 8/2/1/1 PRS 1

Musc.sque
L 4-15 Superf



TECHNIQUE de l'ESP Block

- **-SONDE: linéaire**
- **-POSITION: DL ou Assise**
- **-AIGUILLE: 22 G 5-10cm**
- **-VOLUME: 20 – 30 ml**






ELSEVIER

Contents lists available at ScienceDirect

Arthroplasty Today

journal homepage: <http://www.arthroplastytoday.org/>



Original research

Continuous Lumbar Plexus Block vs Continuous Lumbar Erector Spinae Plane Block for Postoperative Pain Control After Revision Total Hip Arthroplasty

Amy Chen, MD^a, Kerstin Kolodzie, MD, PhD, MAS^{a, b}, Alison Schultz, MD^a, Erik Nathan Hansen, MD^{c, *}, Matthias Braehler, MD, PhD^a

Conclusions: There was no significant difference in opioid consumption and pain scores in patients with continuous LESPB compared with those with continuous LPB. While our study did not show a difference in these outcomes, the LESPB is a straightforward regional block that avoids many of the risks of LPBs and may be as effective for pain control.

© 2021 The Authors. Published by Elsevier Inc. on behalf of The American Association of Hip and Knee Surgeons. This is an open access article under the CC BY-NC-ND license (<http://creativecommons.org/licenses/by-nc-nd/4.0/>).

Anesthesie.club

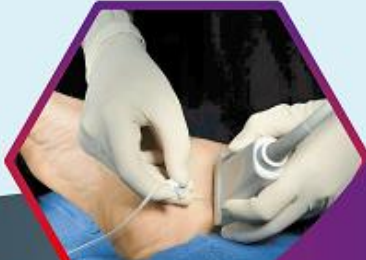MASTERCLASS D'ANESTHÉSIE RÉGIONALE DE CONSTANTINE

MARC

alr La site de l'Anesthésie Locco Régionale Francophone



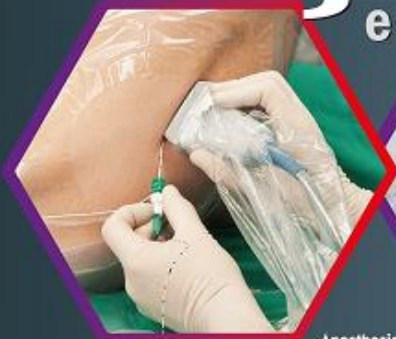Maïssa Lyne ميسالين



MASTERCLASS

- M1 Anesthésie régionale échoguidée
- M2 POCUS (échographie au point d'intervention)
- M3 Online de dissection accrédité par l'EACCME

3 MASTER CLASS en 1



Anesthesie.club



www.anesthesie.club

www.anesthesie.club

Constantine

19,20,21 MAI 2023